NYU Langone
MEDICAL CENTER

2016 / YEAR IN REVIEW

Otolaryngology—Head & Neck Surgery

200 +
COCHLEAR IMPLANT PROCEDURES PERFORMED ANNUALLY

14
ONGOING CLINICAL TRIALS

INNOVATIVE
IMAGING OF CENTRAL AUDITORY PATHWAYS

Contents

Dear Colleagues and Friends:

J. THOMAS ROLAND JR., MD

Mendik Foundation Professor of Otolaryngology

Professor of Neurosurgery

Chair, Department of Otolaryngology—
Head and Neck Surgery

The Department of Otolaryngology—Head and Neck Surgery's consistent ranking among the nation's top programs is, in part, a testament to our cross-disciplinary expertise. We take a collaborative approach, partnering with colleagues across the Medical Center to apply innovation in the most complex cases.

Our progress in treating head and neck cancers is a case in point. With new three-dimensional techniques and surgical procedures, our team of surgeons, oncologists, radiologists, and pathologists work together to virtually plan complex resections—with superior medical and cosmetic outcomes. In this report, you will find a fascinating case in which our surgeons partnered with the Department of Neurosurgery, using nasal endoscopy to reverse disease, and with facial plastic surgeons to restore appearance after the removal of disfiguring lesions.

We also feature several cases that highlight our unique approach to NF2 tumors. As a select Neurofibromatosis Clinical Trials Consortium site and a high-volume center for acoustic neuroma treatment, our renowned team brings cross-disciplinary innovation to patients with these conditions. In one case, our plastic surgeons successfully transferred the masseteric nerve to reanimate a patient's facial muscles after an acoustic neuroma resection—a procedure offered in only a handful of centers.

Many patients have their hearing restored through our nationally recognized Cochlear Implant Center. There, multidisciplinary specialists evaluate patients for both cochlear implants and auditory brainstem implants (ABIs). The center's translational research has resulted in meaningful improvements for patients, including the use of cochlear implants to assist patients with single-sided deafness in noisy environments.

Similar initiatives in our other centers are restoring function, along with quality of life. Research at our Voice Center suggests that stem cells may help regenerate damaged vocal fold tissue, which could impact people's daily lives and, for the voice professionals we serve, livelihoods. In addition, we are building a reputation as a top center treating dizziness from both vestibular and neurological perspectives. Our expertise in this area spans the full care spectrum, from basic research to customized physical therapy at Rusk Rehabilitation.

Serving our youngest patients, the Gastroesophageal, Upper Airway, and Respiratory Diseases (GUARD) Center at Hassenfeld Children's Hospital of New York at NYU Langone is an international referral hub for congenital or acquired craniofacial malformations. Along with reconstructive procedures, the GUARD center is one of only a few centers that can perform pediatric vocal fold reanimations, restoring nerve function in children with vocal fold paralysis following cardiac or thoracic surgery.

We reach these new frontiers in care thanks in part to our ambitious translational research agenda, propelled forward this year by expanded pediatric ABI applications and the advent of more advanced techniques for the diagnosis of Ménière's disease.

As we grow our footprint and our faculty, we remain focused on delivering the highest-quality services to our patients. Through our dedicated efforts in 2016, we achieved measurable care improvements, including total elimination of "never events" and reduced time to discharge. With these and other initiatives, our multidisciplinary collaborations are resulting in new standards of excellence in clinical care. It is my pleasure to familiarize you with our talented team of scientists, clinicians, and trainees in the pages that follow.

Department of Otolaryngology—Head & Neck Surgery

3,500+

PATIENTS HAVE RECEIVED COCHLEAR IMPLANTS AND AUDITORY BRAINSTEM IMPLANTS

at NYU Langone since 1984

200+

COCHLEAR IMPLANT PROCEDURES

performed per year

150+ CHILDREN

UNDER 1 YEAR OF AGE

have received cochlear implants at NYU Langone in the last 14 years

FIRST PEDIATRIC ABI

IN THE COUNTRY

was performed at NYU Langone in 2012, and 11 have been performed as of year-end 2016

ONLY ABI CENTER

FOR NF2 IN THE REGION

and

1 OF 4 ABI CENTERS

WITH FDA TRIALS IN PEDIATRIC ABIs

NOISE CANCELLATION PATENT

PENDING FOR USE IN COCHLEAR IMPLANTS

NATIONALLY RANKED

for Ear, Nose & Throat in *U.S. News & World Report*'s Best Hospitals

BEST HOSPITALS U.S.News & WORLD REPORT NATIONAL EAR, NOSE & THROAT 2016–17

Represents FY16 (Sept 2015–Aug 2016) unless otherwise noted

4 NEW FACULTY MEMBERS

11 ACTIVE NIH GRANTS

14 ONGOING CLINICAL TRIALS

IN HEAD & NECK CANCER, OTOLOGY/NEUROTOLOGY, LARYNGOLOGY, AND PEDIATRIC OTOLARYNGOLOGY

3 NEW CLINICAL TRIALS

NYU Langone Medical Center

10

IN THE NATION
BEST HOSPITALS

and nationally ranked in 12 specialties, including top 10 rankings in Orthopaedics, Geriatrics, Neurology & Neurosurgery, Rheumatology, Rehabilitation, Cardiology & Heart Surgery, and Urology. Nationally ranked in Cancer, Diabetes & Endocrinology, Ear, Nose & Throat, Gastroenterology & GI Surgery, and Pulmonology

11

IN THE NATION
BEST MEDICAL SCHOOLS
FOR RESEARCH

and a leader in innovation in medical education, including accelerated pathways to the MD degree

LEADER

IN QUALITY CARE AND
PATIENT SAFETY

and recognized for superior performance as measured by Vizient's nationwide 2016 Quality and Accountability Study



Expanding Research, Enhancing Expertise

NYU Langone Gathers Worldwide Experts on NF2 and Schwannomatosis

Since its inception in 2007, the Comprehensive Neurofibromatosis (NF) Center at NYU Langone has emerged as an internationally recognized leader in NF and schwannomatosis patient care, clinical trials, and research. In spring 2016, NYU Langone gathered leading experts from around the world for conferences to discuss recent advances in research and treatment of Neurofibromatosis Type 2 (NF2) and schwannomatosis. The first international Schwannomatosis Conference, chaired by Kaleb H. Yohay, MD, associate professor of clinical neurology and pediatrics and co-director of the Comprehensive Neurofibromatosis Center, was the first scientific symposium devoted solely to this rare disease.

Last year's NF2: State of the Art conference, the fifth and largest of these biennial international meetings, attracted more than 120 researchers and clinicians devoted to advancing care and improving quality of life for children and adults affected by this rare genetic disorder. The conference was chaired by Matthias A. Karajannis, MD, associate professor of pediatrics and otolaryngology and director of the Neurofibromatosis Clinical Research Program, J. Thomas Roland Jr., MD, the Mendik Foundation Professor of Otolaryngology, professor of neurosurgery, chair of the Department of Otolaryngology—Head and Neck Surgery, and co-director of NYU Langone's Cochlear Implant Center, and Filippo G. Giancotti, MD, PhD, professor of cancer biology at the University of Texas MD Anderson Cancer Center.

Participants, including leaders from the world's largest NF centers and clinics, discussed ongoing basic and preclinical research, emerging novel therapies and clinical trials, as well as the latest surgical techniques and technologies aimed at improving quality of life.

"Until we can cure NF2, quality of life is where we can make the biggest impact," says Dr. Karajannis. "At NYU Langone, we take a multidisciplinary approach to address the most common functional problems related to this condition, including voice and swallowing issues, facial function, and hearing loss."

↑ Kaleb H. Yohay, MD

Voice Center: New Faculty Members Combine Musical and Clinical Expertise

PAUL E. KWAK, MD, MM, MSc, a laryngologist, joined the faculty of the Voice Center in summer 2016 as assistant professor of otolaryngology—head and neck surgery. Dr. Kwak, who holds a master's degree in music from New York's famed Juilliard School, and who was trained as a professional musician in Juilliard's graduate collaborative piano program, brings a unique background to the Voice Center.

In his clinical practice, Dr. Kwak treats professional singers and actors, young singers-in-training, and patients with vocal cord cancer, vocal cord paralysis, and laryngeal papilloma, and is trained in laryngeal microsurgery and KTP laser treatment. "My multidisciplinary training has equipped me with an understanding of the subtleties and complexities of the professional voice, which allows me to take a nuanced approach to both surgical and medical management of voice and laryngeal disorders," he says.

AARON M. JOHNSON, PhD, MM, who joined the Voice Center as assistant professor of otolaryngology—head and neck surgery also brings a musician's perspective to his care and clinical research. Before becoming a speech-language pathologist, he sang professionally with the Chicago Symphony Chorus.

Dr. Johnson's basic and translational research is focused on understanding and treating voice disorders in older adults. He uses ultrasonic vocalization training in rats to examine the effect of vocal exercise on the muscles and nerves of the larynx and then uses high-resolution three-dimensional MRI to measure changes in laryngeal structure related to aging and vocal exercise. "With our research, we are gaining new insights into how to maintain the health and longevity of the voice as people age," says Dr. Johnson.

↑ Paul E. Kwak, MD, MM, MSc

↑ Aaron M. Johnson, PhD, MM

↑ Kim A. Baker, MD

NEW RECRUIT EXPANDS PEDIATRIC ENT SURGERY OPTIONS IN BROOKLYN

Kim A. Baker, MD, has been recruited as clinical assistant professor and director of pediatric otolaryngology—head and neck surgery at NYU Lutheran Medical Center, bringing new care options to pediatric patients in Brooklyn. Dr. Baker specializes in treating children with complex conditions, such as congenital head and neck masses and disorders of the upper respiratory tract, as well as routine pediatric ear, nose, and throat concerns.

She will split her time between the Brooklyn and Manhattan campuses, so patients can undergo evaluation and treatment for these conditions right in their own neighborhood or at NYU Langone's Hassenfeld Children's Hospital, which is scheduled to open in Manhattan in 2018.

"Dr. Baker's appointment expands the presence of pediatric ENT services in our growing network, while adding highly specialized surgical expertise for our patients," says J. Thomas Roland Jr., MD, the Mendik Foundation Professor of Otolaryngology, professor of Neurosurgery, and chair of the Department of Otolaryngology—Head and Neck Surgery.

DIAGNOSTIC STUDY MAY MORE PRECISELY PINPOINT MÉNIÈRE'S DISEASE

New research under way in NYU Langone's Department of Radiology may give clinicians more effective techniques for diagnosing Ménière's disease. Caused by excessive buildup of endolymph in the cochlear canal, Ménière's disease is usually triggered by disease or trauma but can be idiopathic.

No definitive test for the condition exists; clinicians must instead navigate its complex of symptoms, including vertigo, tinnitus, ear fullness, and hearing loss. Mari Hagiwara, MD, assistant professor of radiology, and Timothy Shepherd, MD, assistant professor of radiology, are conducting a study with the aim of developing a more precise diagnostic technique using MRI.

Study subjects will undergo two high-resolution MRI scans of their inner ears, four hours apart, using intravenous contrast and delayed three-dimensional color map images. This method allows for potential visualization of the endolymphatic space of the inner ear, enabling researchers to detect changes in the volume of the space. The investigative team hypothesizes that with this technique, clinicians can confirm clinical suspicions and more effectively diagnose Ménière's disease, especially in cases that do not precisely fit clinical guidelines.

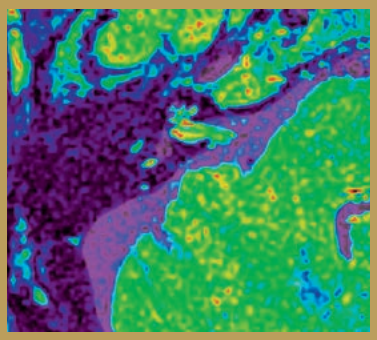

↑ High-resolution images and color map are generated to identify abnormalities of the inner ear seen in Ménière's disease

Adding Surgery to Standard Therapy May Improve Late-Stage Tonsil Cancer Outcomes

Chemotherapy plus radiation is the standard treatment for patients with advanced tonsil squamous cell carcinoma (SCC). Recent research at NYU Langone found that combining this standard treatment with surgery may lead to improved patient outcomes.

In a study led by Babak Givi, MD, clinical assistant professor of otolaryngology—head and neck surgery, researchers compared outcomes of 18,000 adults under age 70 who underwent concurrent chemoradiation therapy (CCRT), surgery plus radiation, or surgery plus CCRT for advanced tonsil SCC. Surgery plus CCRT yielded the highest overall survival of the three treatments—almost 84 percent, compared with 77 percent for surgery plus radiation, and 66 percent for CCRT alone.

At the July 2016 international meeting of the American Head & Neck Society in Seattle, Dr. Givi said that these findings suggest that an initial surgery followed by appropriate adjuvant therapy may be a more efficacious approach for patients with advanced tonsil cancer. He added that newer minimally invasive surgical techniques minimize the risks associated with conventional surgery, making it a viable option for older patients with comorbidities.

New Behavioral Model May Enhance Cochlear Implant Performance

Cochlear implants help many profoundly deaf patients regain hearing, but it remains unclear why some patients respond better than others over time. To explore this issue, Robert C. Froemke, PhD, assistant professor of otolaryngology—head and neck surgery and neuroscience and physiology, and Mario A. Svirsky, PhD, the Noel L. Cohen Professor of Hearing Science and professor of neuroscience and physiology, designed and tested an automated behavioral training system in deaf rats fitted with eight-channel cochlear implants.

The researchers, along with MD-PhD student Julia King, conditioned the rats to perform certain tasks in response to various levels of stimulation. They found that the rats could eventually detect and differentiate between sounds that activated different areas of their brain. These results, published in the June 2016 issue of the *Journal of Neurophysiology*, suggest that altering the stimulation parameters of cochlear implants can help the brain distinguish between signals, leading to improved sound perception. Dr. Froemke hopes to eventually adapt the training system to improve cochlear implant performance in humans.

The research is the result of a multidisciplinary collaboration applying animal research to answer basic questions about hearing and perception that will improve patient care. Dr. Froemke's group is also using recording devices to monitor brain activity during cochlear implant use and training. The recordings will be used to elucidate how the brain changes as subjects learn to "hear again" with cochlear implants; clinicians can use this information to adjust implant stimulation and training procedures to enhance the efficacy of these devices.

↑ Scott M. Rickert, MD

Awards & Recognition

→ **Ryan C. Branski, PhD,** was named standing member of the Motor Function, Speech, and Rehabilitation Study Section by the National Institutes of Health.

→ **Robert C. Froemke, PhD,** was selected as a 2016 Howard Hughes Medical Institute Faculty Scholar, recognizing early-career scientists with great potential to make unique contributions to their field.

→ **Babak Givi, MD,** was elected chair of the Education Committee of the American Head & Neck Society, and began development of the widely anticipated, comprehensive Head and Neck oncology database.

→ **Aaron M. Johnson, PhD, MM,** was invited to serve on the editorial board of the *American Journal of Speech–Language Pathology.*

→ **Judy W. Lee, MD,** has been promoted to division chief of Facial Plastic and Reconstructive Surgery. In 2015, Dr. Lee was elected chair of the American Academy of Facial Plastic and Reconstructive Surgery (AAFPRS) Fellowship Research Review Subcommittee.

→ **Mark S. Persky, MD,** recently established a multidisciplinary Vascular Anomalies Conference at NYU Langone.

→ **Scott M. Rickert, MD,** was named chair of the American Society of Pediatric Otolaryngology's Information Technology Committee

→ **Susan B. Waltzman, PhD,** was appointed to the board of the Cochlear Implant Access Network, whose mission is to enhance access to cochlear implants in emerging countries.

National Institutes of Health Grants

Neural Circuitry for State-Dependent Control of Cortical Auditory Processing and Perception
PI: Ioana Carcea, PhD

Neuroplasticity and Cochlear Implant Use in Rodents
PI: Julia King

Neural Circuitry for Flexible Control of Auditory Perception and Behavior
PI: Kishore Kuchibhotla, PhD

Adaptation to Frequency-Place Functions in Cochlear Implant Users*
PI: Mario A. Svirsky, PhD

Translational Study of Vocal Exercise Dose-Response
PI: Aaron M. Johnson, PhD, MM

Optimal RNA-Based Therapeutics for Vocal Fold Injury and Fibrosis
PI: Ryan C. Branski, PhD

Synaptic Basis of Perceptual Learning in Primary Auditory Cortex
PI: Robert C. Froemke, PhD

Reduction in Spread of Excitation as Predictor Multi-Channel Spectral Resolution
PI: David M. Landsberger, PhD

Synaptic and Circuit Mechanisms of Learned Vocal Production
PI: Michael A. Long, PhD

Developmental Influences on the Functional Organization of the Vestibular System
PI: David E. Schoppik, PhD

Clinical Management of Cochlear Implant Patients with Contralateral Hearing Aids
PI: Mario A. Svirsky, PhD, et al.

*Originally funded in 1999, this is the longest standing federally funded grant in the department.

Ongoing Clinical Trials

A Phase II, Randomized, Double-Blind Placebo Controlled Study to Evaluate the Safety and Efficacy of Azficel-T for the Treatment of Vocal Fold Scarring and Age-Related Dysphonia
PI: Milan R. Amin, MD

Effectiveness of Steroids in the Treatment of Benign Vocal Fold Lesions
PI: Milan R. Amin, MD

Investigation of Human Laryngeal Evoked Brainstem Potentials
PI: Milan R. Amin, MD

Neurogenic Dysphonia/Dysphagia Registry
PI: Milan R. Amin, MD

A 6-Month, Multicenter, Phase 3, Open-Label Extension Safety Study of OTO-104 Given at 3-Month Intervals by Intratympanic Injection in Subjects with Unilateral Ménière's Disease
PI: Paul E. Hammerschlag, MD

Spectral and Temporal Resolution in the Apex
PI: David M. Landsberger

Microdebrider-Assisted Inferior Turbinoplasty Versus Submucous Resections
PI: Seth M. Lieberman, MD

Auditory Brainstem Implant (ABI) in Children with No Cochleae or Auditory Nerves
PI: J. Thomas Roland Jr., MD

Implantation of the HiRes 90K™ Advantage Cochlear Implant with HiFocus™ Mid-Scala and Development of a Combined Electric and Acoustic Stimulation Technology in Adults with Partial Deafness
PI: J. Thomas Roland Jr., MD

Implantation with the Nucleus® CI532 Cochlear Implant in Adults
PI: J. Thomas Roland Jr., MD

A Proposal to Evaluate Revised Indications for Cochlear Implant Candidacy for the Adult CMS Population
PI: Susan B. Waltzman, PhD

Investigation of the FAST Sound Coding Strategy in Newly Implanted Adult Cochlear Implant Recipients
PI: Susan B. Waltzman, PhD

Post Approval Study: Extended Duration Monitoring of Subjects with the Cochlear™ Nucleus® Hybrid™ L24 Cochlear Implant System
PI: Susan B. Waltzman, PhD

Usability of the CP950 Sound Processor with Experienced Cochlear Implant Users
PI: Susan B. Waltzman, PhD

Select Conference Highlights

→ **Ryan C. Branski, PhD,** moderated a panel on multidisciplinary management of vocal fold scarring at the Fall Voice Conference in Scottsdale, Arizona.

→ **Aaron M. Johnson, PhD, MM,** was an invited speaker at a pre-conference workshop, the Mature Vocal Athlete, at the Fall Voice Conference in Scottsdale, Arizona, and delivered a research presentation at the American Speech-Language Hearing Association Convention in Philadelphia, Pennsylvania.

→ **Seth M. Lieberman, MD,** served as a panel moderator and lecturer at the New York Advanced Rhinology and Sinus Surgery Course at Weill Cornell Medical College in New York City, and was a lecturer at the International Endoscopic Sinonasal and Skull Base Anatomy and Surgical Techniques Course in West Palm Beach, Florida.

→ **Mark S. Persky, MD,** served as visiting professor and guest lecturer at the Queen City ENT Symposium hosted by the Department of Otolaryngology, University of Cincinnati in Cincinnati, Ohio, holds an annual visiting professorship at the Rabin Medical Center's Department of Otolaryngology in Petah Tikvah, Israel, and has been invited as a visiting professor by the Department of Otolaryngology at Georgetown University in Washington, DC.

→ **Scott M. Rickert, MD,** was an invited speaker at the European Society of Pediatric Otorhinolaryngology meeting in Lisbon, Portugal, a panelist at the American Cleft Palate Association meeting in Atlanta, Georgia, and in a mini-seminar of the AAO-HNS annual meeting in San Diego, California, and an expert panelist at the George A. Sisson International Workshop in Vail, Colorado.

→ **Susan B. Waltzman, PhD,** delivered presentations at the Middle East Otolaryngology Conference in Dubai, United Arab Emirates, at the VA Appalachian Spring Meeting in Johnson City, Tennessee, and at Cochlear Implant Week in Buenos Aires, Argentina.

→ **J. Thomas Roland Jr., MD,** served as conference chair, abstract committee member, and expert panelist at the 2016 NF2 State of the Art Conference in New York City and as moderator of a panel discussion on complex facial nerve cases at the 26th annual North American Skull Base Society meeting in Scottsdale, Arizona.

→ **Mario A. Svirsky, PhD,** delivered a keynote presentation about music perception as well as one on communicative outcomes in cochlear implant users at the 2016 European Conference of Phoniatrics in Bilbao, Spain, and presented at The Cochlear Corporation Global Research Symposium in Sydney, Australia.

↑ Milan R. Amin, MD, and Ryan C. Branski, PhD

New Frontiers in Clinical Care

NOVEL APPROACHES AND EVIDENCE-BASED TREATMENTS, COMBINED WITH ENHANCED COLLABORATION ACROSS DISCIPLINES, ARE YIELDING NEW POSSIBILITIES FOR OUR PATIENTS.

↑ J. Thomas Roland Jr., MD (left) and David R. Friedmann, MD (right)

Advancing the Science of Cochlear Implants

NYU Langone surgeons first implanted a multichannel cochlear prosthesis in an adult more than 30 years ago, and since that time, the Medical Center has continued to dedicate significant resources and expertise to advancing cochlear implant science.

Today, new discoveries at the Cochlear Implant Center are both expanding the clinical use of cochlear implants and enhancing the efficacy of implant technology. Over the past year, several advances—from a new algorithm to a new application in single-sided deafness—have created new, life-enhancing possibilities for patients with hearing loss.

COCHLEAR IMPLANTS MAY REPLICATE BINAURAL HEARING IN SOME PATIENTS WITH SINGLE-SIDED DEAFNESS

People who experience deafness in one ear—single sided deafness, or SSD—often have trouble interpreting sounds and communicating, especially in noisy environments. Hearing aids are the recommended treatment for these patients, but recent NYU Langone research suggests that cochlear implants may be an effective treatment alternative.

"Individuals who cannot hear out of both ears have trouble localizing sound as well as understanding speech in a noisy situation," says Susan B. Waltzman, PhD, the Marica F. Vilcek Professor of Otolaryngology and co-director of the Cochlear Implant Center. "Hearing aids can amplify sound when there is residual hearing, but do not help when there is hearing loss. Other possible treatments, such as bone-anchored hearing aids, do not restore hearing to the affected ear."

Cochlear implants may create this single-ear pathway by stimulating the auditory nerve and restoring hearing to the affected ear. As a result, they have the potential to replicate the benefits of binaural hearing by enabling SSD patients to tell where sounds are coming from, and to distinguish speech from background noise.

In a recent review of procedures performed at the Cochlear Implant Center, researchers reported significant improvement in speech perception with cochlear implants in 12 adult and 4 pediatric patients with SSD. The study, published in the February 2016 issue of *Otology & Neurotology,* suggests that cochlear implants are a viable treatment option for SSD and can lead to significant improvements in quality of life, according to lead investigator David R. Friedmann, MD, assistant professor of otolaryngology—head and neck surgery. Dr. Waltzman and J. Thomas Roland Jr., MD, the Mendik Foundation Professor of Otolaryngology, professor of neurosurgery, chair of the Department of Otolaryngology—Head and Neck Surgery, and co-director of the Cochlear Implant Center, are among the study's coauthors.

"Cochlear implants may overcome some of the issues patients encounter with CROS [cross-routing of sound amplification devices] and bone-anchored hearing aids," adds Dr. Roland.

In the study, patients with the implants significantly improved on several important measurements, including word recognition and signal-to-noise ratio.

Despite their potential benefits, physicians should make sure patients understand that their use cannot completely restore normal hearing, notes Dr. Roland. Cochlear implants are not yet FDA-approved for SSD.

"It's crucial to have an informed discussion with patients and families about the risks and benefits of all available therapies," he says. "Our experience suggests that cochlear implantation may offer appropriate patients the best opportunity to realize the benefits of binaural hearing, but further study is required before this treatment modality can be more widely advocated."

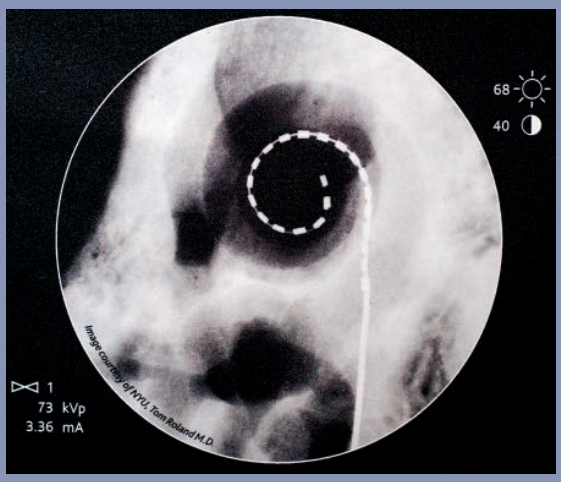

↑ Cochlear™ Nucleus® Profile Implant with Slim Modiolar Electrode

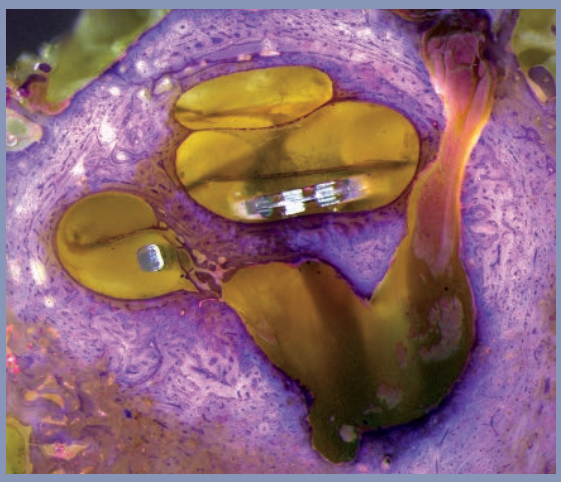

↑ New perimodiolar electrode inside a human cochlea

NEW COCHLEAR IMPLANT ELECTRODE IMPROVES HEARING, REDUCES TRAUMA

Researchers at NYU Langone's Cochlear Implant Center are testing a new electrode that promises to deliver improved hearing performance for patients with severe to profound auditory loss. The perimodiolar electrode's slim design allows it to be positioned closer to the auditory nerve than traditional implant electrodes, thus delivering more precise nerve stimulation. In addition, it has a flexible insertion mechanism that reduces the risk of trauma to the inner ear.

NYU Langone has implanted the electrodes in many adults and children with encouraging results, says J. Thomas Roland Jr., MD, the Mendik Foundation Professor of Otolaryngology, professor of neurosurgery, chair of the Department of Otolaryngology—Head and Neck Surgery, and co-director of the Cochlear Implant Center. Hearing was preserved in most patients who had measurable hearing prior to implantation—more than 80 adults and children—and speech perception continues to improve in all patients. In addition, researchers at the Cochlear Implant Center participated in a study mandated by the U.S. Food and Drug Administration that demonstrated safe and effective implantation of the device can be readily learned by inexperienced surgeons with the center's well-defined training module.

STUDY SHOWS COUNSELING SUPPORTS CONTINUED IMPROVEMENT

Until recently, patients were expected to reach a plateau in speech perception within the first year after implant surgery, says Dr. Waltzman. However, research at the Cochlear Implant Center now shows that with the improved technology and surgical techniques of the past decade, many patients make significant progress in speech understanding for up to five years.

NYU Langone investigators conducted a retrospective review of adults who had completed at least two years of therapy after receiving implants. Significant improvements in speech perception were observed for three years in patients who became deaf after age two (postlingual) and for five years in patients whose deafness occurred between birth and age two (prelingual).

The findings are particularly helpful for physicians and audiologists counseling patients after surgery, since effective counseling can help patients realize the full benefits of their cochlear implants, notes Dr. Waltzman.

"Cochlear implants don't always work well immediately, and patients can become frustrated," she says. "We can now confidently advise patients that their speech perception is likely to continue improving well beyond the first year."

EMOTIONAL EFFECT OF MUSIC DELIVERED BY COCHLEAR IMPLANTS

Cochlear implants have been optimized for communication and speech perception, but little is known about how well they relay nonverbal cues in speech and music. As a musician and neurotologist, David R. Friedmann, MD, assistant professor of otolaryngology—head and neck surgery set out to understand—and ultimately improve—patients' ability to perceive emotion in music and the impact of this perception on music enjoyment.

"Previous studies suggest that the complexities of music are not well preserved for cochlear implant users," says Dr. Friedmann. "That led me to wonder whether they perceive the emotional content behind songs—a motivation for many individuals with normal hearing listening to music."

Dr. Friedmann determined whether cochlear implant users could identify the emotion associated with short musical clips. Twenty patients, ranging in age from 15 to 80 years, participated in the study. An iPad app created by Daniel Jethanamest, MD, director of the Division of Otology-Neurotology and assistant professor of otolaryngology—head and neck surgery, was used to administer the test, wherein users rated their emotional perception of 20 pieces of music with varying emotional underpinnings, presented in a random order. A background questionnaire was also developed to evaluate patients' relationship with music both after hearing loss and after implantation.

Cochlear implant users accurately matched emotions—such as happy, sad, scary, or peaceful—to the appropriate songs about half the time, compared to 90 percent accuracy in patients with normal hearing. Dr. Friedmann notes that the findings could impact future research aimed at improving cochlear implant technology.

"A lot of the current research looks at the technical aspects of music perception, such as determining whether one pitch is higher or lower than another, and not on the mood it evokes," he says. "These findings suggest that users' emotional experience may be a more important factor to study to improve music enjoyment in those with cochlear implants."

NEW INDICATIONS FOR SINGLE-SIDED DEAFNESS

With the results and observations from subsequent patient evaluations, researchers recommend three indications for considering implants in patients with SSD:

→ **Late-stage unilateral Ménière's disease.** Cochlear implants have been shown to rehabilitate hearing in patients who progress to SSD as a result of this condition.

→ **An at-risk hearing ear.** Although rare, an acoustic neuroma or other retrocochlear pathology can threaten the hearing ear, leading to sudden total deafness. Early, preemptive cochlear implantation can improve outcomes and help patients adjust if they lose hearing in the threatened ear.

→ **Pediatric progressive hearing loss.** Implantation may improve outcomes in younger patients whose good ear is likely to decline because of progressive conditions such as an enlarged vestibular aqueduct, genetic abnormalities, autoimmune inner ear disease, ototoxicity, and certain metabolic diseases.

NEW ALGORITHM BLOCKS AMBIENT BABBLE, BOOSTS UNDERSTANDING

Excess ambient babble—or background noise produced by competing talkers—can make it difficult for patients with cochlear implants to hold conversations. Although most noise suppression algorithms use a conventional temporal and spectral approach to blocking out nonverbal sounds such as road traffic or air conditioners, these methods do not work as well to isolate the similar, overlapping frequencies of voices in a crowd. To address this problem, researchers at NYU Langone and the NYU Tandon School of Engineering developed a novel noise-reduction algorithm called Speech Enhancement using Decomposition Approach (SEDA) for use in cochlear implants.

The research team—Ivan W. Selesnick, PhD, professor of electrical and computer engineering, David M. Landsberger, PhD, assistant professor of otolaryngology—head and neck surgery, and electrical engineering doctoral student Roozbeh Soleymani—took a novel approach. Their algorithm blocks ambient babble by decomposing speech signals into

waveforms based on the duration or sustainability of disparate voice oscillations. This decomposition, in an oversampled wavelet domain, makes it easier for SEDA to differentiate—and eventually attenuate—components originating from the babble. When SEDA is used to process sound in the context of ambient babble, it boosts cochlear implant users' rates of understanding by up to 25 percent over understanding without SEDA.

Researchers noted that the innovation, which is awaiting patent approval, may have far-reaching applications beyond helping the hearing impaired. The group is working on implementing a fast version of the algorithm for cell phones, so it can be evaluated for use in daily life by the general population.

"Someone making a call from a crowded restaurant theoretically would be able to hold a conversation without interference from background noise," explains Dr. Landsberger. "SEDA was conceived as a way to improve the performance of cochlear implants, but it could be useful in any situation where hearing is impeded by noise."

COCHLEAR IMPLANTS MAY SLOW DEMENTIA

Research emerging from the Cochlear Implant Center suggests that cochlear implants may slow the onset of dementia in elderly patients with profound hearing loss.

Investigators followed a cohort of seven elderly cochlear implant recipients, assessing their performance on a battery of neurocognitive tests before and up to four years after implantation. Progressive improvement was observed on 70 percent of the tests, with the biggest gains seen in verbal comprehension and memory. The study was published in the May 2016 issue of *Clinical Interventions in Aging.*

Brain plasticity may underlie the neurocognitive improvements following implantation, the study authors note. Previous studies in both animals and humans have demonstrated that electrical stimulation with a cochlear implant triggers changes in neural response patterns and cortical organization of the central auditory system.

Although other studies have noted the effect of cochlear implants on speech perception, the connection between implantation and cognition has yet to be fully examined, says senior author Susan B. Waltzman, PhD, the Marica F. Vilcek Professor of Otolaryngology and co-director of the Cochlear Implant Center. The findings of this study could have important implications for dementia prevention, considering that there are currently no effective treatments, she adds.

"As the population ages, the individual and public health burden of hearing loss and dementia will grow in scope and importance," says Dr. Waltzman. "Although the research is still in its early stages, cochlear implants may represent an important opportunity for intervention in patients with severe to profound hearing loss and the possibility of cognitive decline."

LOCAL ANESTHESIA OPENS NEW OPTIONS FOR OLDER PATIENTS

To pave the way for cochlear implantation in some older patients, NYU Langone is pioneering the use of local anesthesia during implantation. Researchers are conducting a retrospective review to compare outcomes of patients who received conscious sedation with dexmedetomidine infusion versus general anesthesia. "Since we are using cochlear implants to inhibit cognitive decline and general anesthesia has been shown to actually initiate cognitive decline, mild sedation with local anesthesia makes a lot of sense—especially if it can be done effectively and safely, as early results show it can," says J. Thomas Roland Jr., MD, the Mendik Foundation Professor of Otolaryngology, professor of neurosurgery, chair of the Department of Otolaryngology—Head and Neck Surgery, and co-director of the Cochlear Implant Center.

Dexmedetomidine, which has been used safely in some neurosurgical procedures, is particularly well suited for older patients with cardiopulmonary disease because it preserves normal respirations and limits unwanted general anesthesia effects while providing adequate analgesia. This approach will likely provide an option for cochlear implantation in patients who cannot tolerate general anesthesia because of medical or cognitive issues.

New Advanced Imaging Technique May Predict ABI Efficacy

For patients with sensorineural hearing loss who are not eligible for cochlear implantation, auditory brainstem implants (ABIs) that directly stimulate the cochlear nucleus in the brainstem may provide an effective alternative.

At NYU Langone, researchers are beginning to use noninvasive, advanced diagnostics to elucidate which patients might benefit most from ABIs. Although early studies demonstrated that ABIs can enable speech and sound perception in some patients, outcomes in both adults and children remain under investigation. Since ABIs require an invasive surgical procedure with added risk of infection, continued use of the devices depends on evidence proving their efficacy.

Timothy M. Shepherd, MD, PhD, assistant professor of radiology, J. Thomas Roland Jr., MD, the Mendik Foundation Professor of Otolaryngology, professor of neurosurgery, chair of the Department of Otolaryngology—Head and Neck Surgery, and co-director of the Cochlear Implant Center, and others developed the research protocol, which relies on advanced diffusion and quantitative T2-weighted MRI sequences to predict ABI implantation success. Using recently implemented simultaneous multi-slice diffusion sequences in a clinically feasible 3T MRI protocol, the research team obtains quantitative track density imaging (TDI) preoperatively in ABI candidate patients. Used at NYU Langone in this manner, TDI visualizes for the first time the actual locations of many internal brainstem nuclei with powerful, 500-micron resolution.

"These sequences create super-resolution images of the brain based on post-processing of whole-brain probabilistic tractography streamlines," notes Dr. Shepherd. "They reveal exquisite anatomic detail of white matter fibers and deep gray nuclei."

With this protocol, the research team, which includes radiology resident Misia Yuhasz, MD, and former neuroradiology fellow Michael Hoch, MD, can identify the cochlear nucleus and the auditory white matter tract, from the brainstem to Heschl's gyrus, in healthy young adult controls. In 2017, they will use a similar protocol on pediatric and adult patients with sensorineural hearing loss to compare the density and morphology of the cochlear nucleus and auditory pathway—and to determine whether differences may be used to identify future candidates most likely to benefit from ABI.

"In addition to helping us predict which patients should appropriately receive a cochlear implant or an ABI, we are hopeful that our results will also enhance our understanding of hearing pathways in novel ways," says Dr. Roland. "The work capitalizes on the unique juxtaposition of imaging expertise and cochlear implant/ABI capabilities found at NYU Langone," he adds.

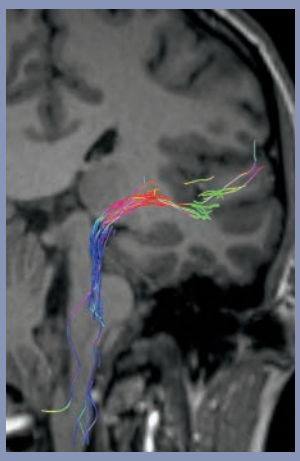

↑ TDI tractography of the auditory pathway

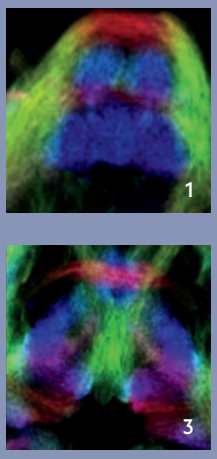

(1) Ponto-medullary junction

(2) Caudal midbrain

(3) Thalamus

↑ Direction-encoded color track density imaging (DEC-TDI) of the auditory pathway

One Tumor, Many Pathways: Acoustic Neuroma Management Takes a Patient-Specific Approach

New treatment pathways, leveraging novel surgical approaches and expanded device applications, have increased the options for hearing-restorative treatment for patients with NF2 tumors, including acoustic neuromas.

REAL-TIME SURGICAL FINDINGS POINT TO AUDITORY BRAINSTEM IMPLANT FOR NF2 HEARING LOSS

When a 27-year-old male with NF2 presented with an acoustic neuroma that had robbed his right ear of hearing, he was already a veteran of surgery performed at other institutions, including a left-side tumor resection a decade earlier. An auditory brainstem implant (ABI) placed at that time had proved ineffective and left him with no hearing in his left ear. More recently, a right-side middle fossa decompression procedure to relieve pressure on his auditory nerve from the new tumor had failed to stem his hearing loss. Now almost completely deaf, the patient sought a second opinion at NYU Langone, where he consulted with a multidisciplinary team highly experienced in treating the most complex acoustic neuroma cases, including those of prior treatment failure.

TEAM CONSENSUS: TUMOR RESECTION, IMPLANT PLACEMENT

The team was in agreement: the tumor had to come out. The patient also wished to enroll in an NYU Langone clinical trial for axitinib, a multikinase inhibitor that had the potential to prevent NF2 tumor growth by inhibiting the cell proliferation pathway at several points. Taking these factors into account, the team recommended a new surgical plan, involving a cranial nerve-sparing translabyrinthine approach plus right-side installation of either a cochlear implant or an ABI, depending on findings during the tumor resection.

CAREFUL ABI PLACEMENT SIGNIFICANTLY IMPROVES HEARING

Over the course of many acoustic neuroma operations, John G. Golfinos, MD, associate professor of neurosurgery and otolaryngology and chair of the Department of Neurosurgery, and J. Thomas Roland Jr., MD, the Mendik Foundation Professor of Otolaryngology, professor of neurosurgery, and chair of the Department of Otolaryngology—Head and Neck Surgery, have implanted scores of ABIs. These high-tech devices, FDA approved for NF2 patients, restore some hearing after electrodes are placed in the brainstem's auditory region; these electrodes turn sound into brain signals to simulate hearing.

In the current case, once the surgeons accessed the tumor, the team determined that there was not enough residual auditory function to warrant a cochlear implant, leaving the ABI the option of choice. After the tumor was resected, Dr. Roland drilled spaces in the skull to seat the implant and the electrode. Dr. Golfinos, working under high magnification, then opened the foramen to the fourth ventricle and carefully advanced the ABI's electrode paddle into position on the cochlear nuclei inside the brainstem. Final placement of the ABI was fine-tuned on the basis of evoked auditory brainstem response readings, and the electrode paddle was fixed in place using Teflon felt and Gelfoam.

SURGICAL OUTCOME: FUNCTION INTACT, HEARING ENHANCED

Several weeks later, the patient met with the Medical Center's audiologists, who programmed the ABI. The patient's outcome has been excellent; he has 20 active electrode channels and significantly improved hearing. His cranial nerve function remains intact, and he is proceeding with the drug trial as planned.

"We take a multifaceted approach, matching each patient's tumors with the therapeutic and surgical options in our arsenal," says Dr. Roland. "Our ability to fine-tune treatment, even in the midst of surgery, means we're ready to take on the most complex patients—including those who have not responded to prior treatment."

IN ACOUSTIC NEUROMA RESECTION, EXPERIENCE IS A STEADY HAND

The patient, a retiree in his early seventies, first noticed hearing loss on his right side, but wrote it off to a lifetime of working with heavy equipment. But after his right ear went completely deaf, he reluctantly agreed to an MRI scan. A few days later, he found himself in the office of Dr. Golfinos, reviewing an image of a walnut-sized vestibular schwannoma, also known as an acoustic neuroma, pressed against his brainstem.

The scan showed the tumor extending into the patient's auditory canal and compressing his trigeminal and other cranial nerves. In addition to his hearing, it had begun to affect his balance and facial sensation—symptoms that Dr. Golfinos advised would only worsen over time. "I explained to him that watchful waiting was no longer a viable option," says Dr. Golfinos.

"Our ability to fine-tune treatment, even in the midst of surgery, means we're ready to take on the most complex patients—including those who have not responded to prior treatment."

—J. Thomas Roland Jr., MD

Radiosurgery is among the options typically employed to treat acoustic neuromas at the Medical Center. "For this tumor, however, because of its size and degree of brainstem compression, microsurgical resection was the only reasonable treatment," says Dr. Golfinos. "And although it's very difficult to remove these types of tumors entirely, in this case, given the patient's age, we didn't need a total resection."

EXPERIENCE, FACIAL FUNCTION GUIDE SURGICAL APPROACH

Safely detaching an acoustic neuroma from the nerve fibers adhering to it is a demanding operation, and the size and location of this particular tumor heightened the risk of possible nerve damage. Fortunately, the patient found himself with Dr. Golfinos and Dr. Roland, who have performed more than 1,800 acoustic neuroma resections—a record few surgical teams can match.

With the patient's right-ear deafness now permanent, preserving the facial nerve became the top priority. The surgeons chose a translabarynthine transmastoid approach, because it offered the best sightlines for identifying the nerves. Working with an operating microscope, Dr. Roland created access by performing a mastoidectomy and then drilling out the labyrinth, removing bone from the internal auditory canal, and incising two flaps in the dura to expose the tumor. Using a Cavitron Ultrasonic Surgical Aspirator (CUSA), he carefully debulked the center of the tumor, then opened the dura of the internal auditory canal to follow the tumor into the canal. There, he identified the facial nerve and followed it out to the porus, where the nerve became involved with the thicker portion of the tumor.

SEPARATING TUMOR FROM NERVE WITH PRECISION DISSECTION

Dissecting the tumor from the cerebellum down to the brainstem, Dr. Golfinos used the CUSA to open all the tumor's cysts. The tumor was now just a thin shell along the brainstem. While the eighth cranial nerve was still hidden from sight—"likely splayed through and over the back of the tumor cysts," notes Dr. Golfinos—he identified the seventh cranial nerve and the trigeminal nerve and dissected them away from the thin tumor remnant.

"All that remained then was a small amount of tumor, just along the distal trigeminal nerve and along the facial nerve as it went into the internal auditory canal," Dr. Golfinos recalls. With more than 85 percent of the tumor removed and reassuring motor-evoked potential readings of the relevant nerves, the surgeons determined that any additional resection would jeopardize the facial nerve and the brainstem. They closed the surgical site, coagulating any remaining suspicious tissue along the way, and used an abdominal fat graft to patch the dura. With the tumor largely gone and adjoining nerves still intact, an exceptionally difficult surgery was complete. The patient did very well postoperatively, with a complete resolution of his headaches, imbalance, and trigeminal symptoms.

New Tissue Regeneration Treatments Hold Promise for Patients with Vocal Fold Scarring

Vocal fold scarring is a significant problem that can result in a profoundly disordered voice, and clinical efficacy of current treatments is poor. To address this issue, researchers at the Voice Center at NYU Langone are now testing promising new therapies that use noninvasive techniques to stimulate tissue regeneration.

STUDY MAPS PATHWAY FROM STEM CELL TO VOCAL TISSUE

In a recent study, Ryan C. Branski, PhD, associate professor of otolaryngology—head and neck surgery and associate director of the Voice Center, and his research group developed a co-culture model using adult stem cells extracted from rodents treated with transforming growth factor beta (TGF-β) combined with vocal fold fibroblasts. In vitro, this combination suppressed TGF-β signaling, a key mediator of cell differentiation and fibrosis. These findings were published in the June 2016 issue of *The Laryngoscope*.

> *"We have the potential to help millions of patients through the development of novel techniques to rebuild vocal fold tissue in a more favorable way."*
>
> *—Ryan C. Branski, PhD*

Although stem cells are known to promote tissue healing, the underlying mechanisms are unclear, notes Dr. Branski. Results from this study suggest that stem cells direct the formation of new tissue via paracrine signaling in addition to previously described mechanisms. Researchers also noted that stem cells derived from bone marrow produced better results compared with adipose derived or tissue-specific stem cells. Cumulatively, these data can be employed to optimize therapies for patients with vocal fold fibrosis.

"These data provide important insight into how stem cells interact with native cells," says Dr. Branski. "Stem cells appear to hold significant promise to direct the wound-healing process toward a more regenerative outcome."

GENE RESEARCH UNCOVERS THERAPEUTIC TARGET

Gene therapy is another promising avenue of research into new treatments for scarring. Supported by a five-year, $2.1 million National Institutes of Health grant, Dr. Branski and Milan R. Amin, MD, associate professor of otolaryngology—head and neck surgery, chief of the Division of Laryngology, and director of the Voice Center, are investigating the *Smad3* gene as a potential therapeutic target.

Smad3, which encodes for a protein along the TGF signaling pathway, is elevated in injured tissue, and in vocal folds specifically. *Smad3* appears to mediate the fibrotic actions of TGF-β, explains Dr. Branski. Across species in vitro, Dr. Branski and his group discovered that knocking down *Smad3* via small inhibitory RNA decreased the fibrotic response, suggesting that it is likely a promising therapeutic target. Historically, the delivery of gene-based therapies has been problematic. Dr. Branski and his research group, with Kent Kirshenbaum, PhD, professor of chemistry at NYU, refined a lipitoid nanoparticle delivery reagent to increase the efficacy of *Smad3* knockdown in vivo. Preclinical trials are under way.

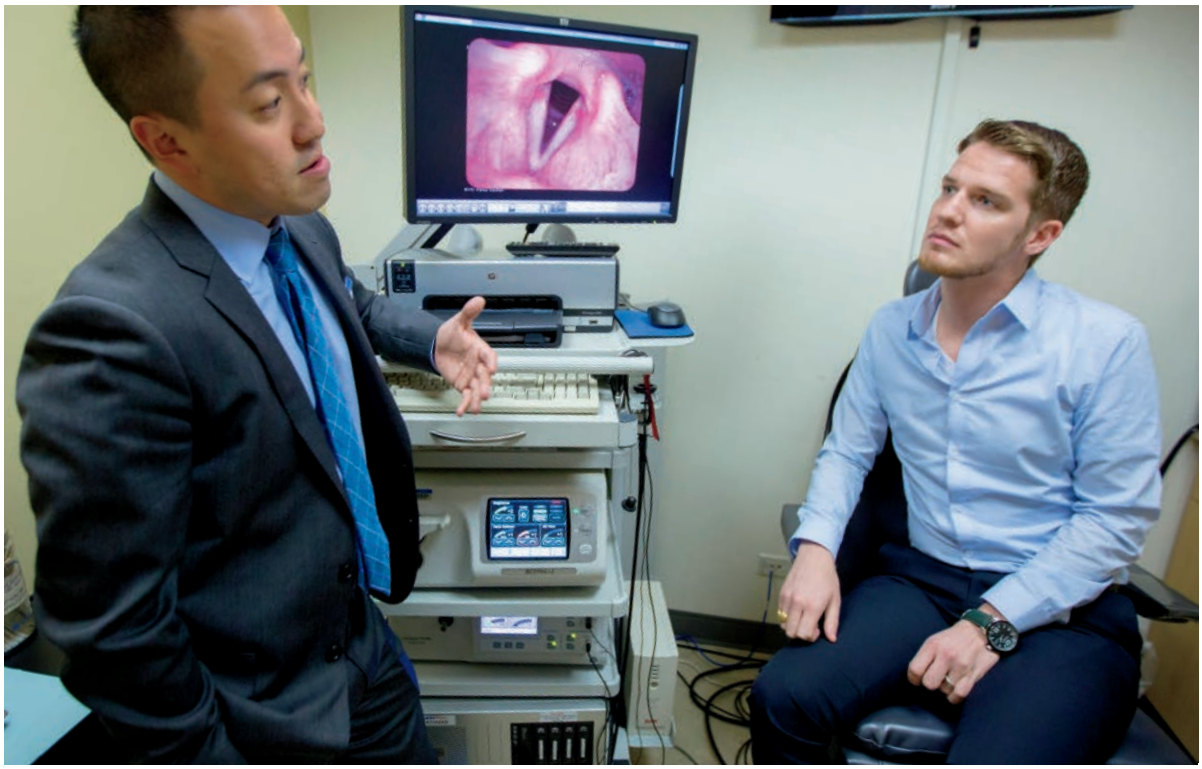

↑ Paul E. Kwak, MD

SCAFFOLDING TECHNIQUE BUILDS FOUNDATION FOR HEALTHY TISSUE

As described in a 2016 review published in *Tissue Engineering Part B: Reviews,* Dr. Branski and colleagues built upon this innovative approach to the rehabilitation of vocal fold injury via tissue engineering approaches, and specifically tissue-specific scaffolds. These scaffolds are derived from vocal fold tissue and maintain naturally occurring proteins, as well as chemical cues embedded within the scaffold to direct more favorable tissue healing. Dr. Branski and collaborators from the New York Stem Cell Foundation and North Carolina State University, recently described a novel technique for purifying these vocal fold–based scaffolds, and are now investigating their biocompatibility both in vitro and in vivo.

"Current treatments for vocal fold scarring—including surgery, steroid injections, and laser treatments—largely fail to restore the native composition, structure, and function of vocal folds, which likely explains the suboptimal outcomes in these challenging patients," says Dr. Branski. "Now we are very close to changing clinical care paradigms for these patients. We have the potential to help millions of patients through the development of novel techniques to rebuild vocal fold tissue in a more favorable way."

Multidisciplinary Surgical Team Enables New Options for Difficult Tumor Resections

Chandra Sen, MD, professor of neurosurgery, admits that he would not have tried a nasal endoscopy on a large skull base tumor 10 years ago—despite being one of the world's preeminent skull base surgeons and one of the few with expertise in both open and endoscopic brain surgery.

Today, however, thanks to improved technology, Dr. Sen is readily using this technique, working with colleagues in the Department of Otolaryngology—Head and Neck Surgery to resect even some large skull base tumors. "In recent years, the instrumentation has gotten better, so we're using this approach more and more," notes Dr. Sen.

CASE PRESENTATION: BRAINSTEM CHORDOMA

In one recent case, a male patient in his forties presented with a walnut-sized tumor—a rare, slow-growing chordoma—that was compressing his brainstem. The patient struggled for breath whenever he lay down, and a respiratory consult at another center led to a brain scan, which revealed the tumor. At a subsequent consult with Dr. Sen, the patient was told the tumor would need to be removed surgically. "Eventually he would have become completely debilitated," says Dr. Sen. "It had to come out."

→ Preoperative axial MRI, showing the tumor pushing into the brainstem

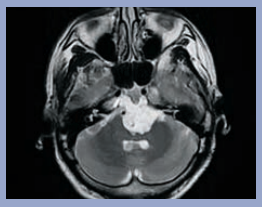

→ After surgery, brainstem has recovered its normal shape

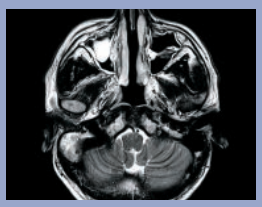

"The patient's tumor was sitting in front of the brainstem, at the center of the head," continues Dr. Sen. "I explained the two different ways we could remove it: we could cut open the skull and come at it from the side, which would mean going through many sensitive areas of the brain, or, since it was at the front of the brainstem, we could take it out endoscopically through the nose."

Because the nasal approach offered a direct path to the tumor, it reduced the likelihood of collateral brain damage, which is why Dr. Sen ultimately recommended this approach to his patient. "Still, the operation had its risks," he says. "He could end up unable to walk or talk properly, or with double vision. So, a very careful resection was required."

A SYNCHRONIZED SURGICAL APPROACH

When the eight-hour operation began, Dr. Sen stood side by side with Richard A. Lebowitz, MD, associate professor of otolaryngology—head and neck surgery. An expert nasal surgeon, Dr. Lebowitz regularly partners with NYU Langone's neurosurgeons to perform endoscopic brain tumor resections.

"I'm responsible for the surgical approach," says Dr. Lebowitz. "My job is to create space so Dr. Sen can reach the tumor, which involves moving—and in some areas removing—various nasal structures." After the surgical team inserted a drain to divert the skull's cerebrospinal fluid during the procedure, Dr. Lebowitz got to work. Elevating the nasal flaps and preserving them for reconstructive use, he took down the back of the septum and cut an opening in the front wall of the sphenoid sinus to provide access to the bone at the back of the sinus.

At that point, Dr. Sen took the lead. With stereotactic navigational guidance, he drilled a silver-dollar–sized hole through the sinus wall into the skull and removed the tumor piecemeal. Keeping an eye on the patient's motor-evoked potentials, Dr. Sen progressed slowly to reach the spot where the tumor pressed into the brainstem.

"Once the central portion of the tumor was debulked," says Dr. Sen, "I established a plane around the tumor against the brainstem." Careful to avoid nearby blood vessels to the brainstem, he exposed the sixth cranial nerve and dissected the tumor away from it, until he had removed the entire tumor. Dr. Lebowitz then took the lead again and patched the hole in the back of the sinus with abdominal fat, then rotated the nasal flaps to cover the patch. In a surgery as finely tuned as this one, the surgeons say they come to be so closely in sync that they operate simultaneously as four hands directed by two sets of eyes.

CASE OUTCOME: FUNCTION PRESERVED, RECOVERY EXPEDITED

With the tumor fully resected, the patient's brainstem quickly resumed its normal position and his symptoms subsided. Some ongoing leakage of cerebrospinal fluid into the nose—a common occurrence—required a minor second procedure, and the patient needed regular visits to have scabs removed from his nasal passages. "The nasal resection is less traumatic than the alternative approach, but it's still a big operation," says Dr. Lebowitz.

The patient was able to resume his normal activities within six weeks after his operation—a significantly faster recovery than would have been likely with a craniotomy. "He basically returned to his life and work without impairment," says Dr. Sen.

By offering a direct approach to the tumor with reduced risk of functional impairment and complications, the endoscopic procedure was clearly the right option for this patient. "If the tumor had been located more laterally, though, I would have been very ready to do a craniotomy instead," notes Dr. Sen. "What makes NYU Langone's skull base practice unique is that we offer the full spectrum of surgical options to meet every patient's needs, so we can choose the option best suited to the situation. This was an especially tough case to do endoscopically—but it was the best option, and in the end, we were able to have a very good impact on the patient's life."

↓ Richard A. Lebowitz, MD

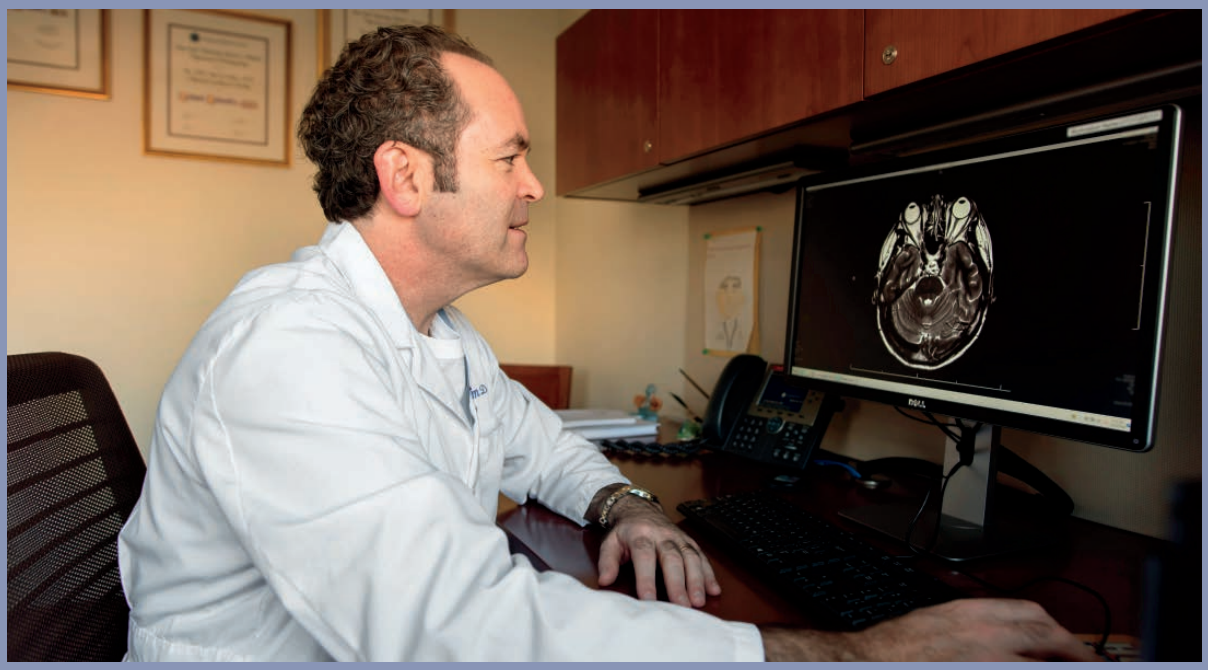

Department Quality Initiatives Achieve Measurable Care Improvements

NYU Langone's consistent recognition by Vizient (formerly the University Health System Consortium) as a top academic medical center for patient safety and quality is largely due to the efforts of physicians who make quality improvement a top priority. Babak Givi, MD, clinical assistant professor of otolaryngology—head and neck surgery and the patient safety–quality improvement officer in the Department of Otolaryngology—Head and Neck Surgery, is one of these physicians.

COMMON GOALS DEFINE QUEST FOR QUALITY

In 2015, Dr. Givi identified three overarching goals: improving timely discharges, eliminating "never events" (such as wrong-side surgery), and lowering preventable adverse events. The efforts put in place to achieve those goals resulted in measurable care enhancements: Between July 2015 and November 2016, the department experienced zero "never events" and increased its discharges before noon from below 20 percent to more than 50 percent, consistently surpassing the set target.

"Everyone on staff should feel accountable for the safety and quality of the care we provide on a daily basis," says Dr. Givi. "To improve, you must set goals and keep everyone informed about continued progress to reach them."

Dr. Givi implemented a real-time tracking system to monitor adverse events, so the department can uncover any systemic problems, address them quickly, and avoid further occurrences. With the system, all adverse events trigger an immediate report and an investigation into the possible cause.

"We're focused on understanding the process underlying the mistake rather than assigning blame, so we can figure out how to fix it," says Dr. Givi.

Dr. Givi has several quality improvement projects in the pipeline, including one to monitor thyroid function in cancer patients who undergo radiation, and another to track the rate of infections in the operating room. These departmental quality improvement efforts are part of a robust Medical Center–wide focus on quality initiatives, reinforced by NYU Langone leadership, including Saul J. Farber Dean and CEO Robert I. Grossman, MD, and Chief Quality Officer Martha J. Radford, MD, MA.

"Improving our operational efficiency goes hand in hand with improving patient care," notes Dr. Givi. "Our efforts so far demonstrate that it's possible to achieve great outcomes without increasing costs or jeopardizing patient safety."

THE DEPARTMENT INCREASED ITS DISCHARGES BEFORE NOON

from

< 20%

to

> 50%

consistently surpassing the set target

Technology Enhances Teamwork in Advanced Head and Neck Surgeries

With the development of high-resolution three-dimensional imaging and computer animation software, surgeons at NYU Langone entered a new era of virtual surgical planning that enables comprehensive surgical approaches for both the oncological extirpation of tumors and the reconstructive challenges presented by these complex defects.

Combining three-dimensional printing techniques with a variety of materials used in craniofacial reconstruction—such as titanium or polyetheretherketone (PEEK)—the head and neck surgical team creates multidimensional, patient-specific implants preoperatively, while preparing for the full range of eventualities that may arise during head and neck procedures in the operating room.

"At NYU Langone, a multidisciplinary team of head and neck surgeons, plastic surgeons, oral-maxillofacial surgeons, and maxillofacial prosthodontists collaborate in three-dimensional surgical planning sessions from the beginning, so we can provide patients with the optimal functional and cosmetic outcome," explains Adam S. Jacobson, MD, associate professor of otolaryngology—head and neck surgery.

The three-dimensional planning process provides several benefits. The creation of an exact surgical plan and patient-specific cutting guides provides a previously unattainable level of precision for surgeons once in the operating room. In addition, preplanned rigid fixation plates are customized to exactly fit the surgical plan, eliminating the need for surgeons to spend time in the operating room bending the plates to fit. If an implant is needed to replicate a missing piece of the cranium, it can be designed according to the virtual surgical plan, which perfectly replicates the patient's original bone. "Using preplanned cutting guides allows for faster, more exact osteotomies during surgery—ultimately allowing for shorter surgeries with better outcomes," says Dr. Jacobson.

HEAD AND NECK CENTER DIRECTOR TO LEAD NATIONAL SOCIETY

Mark S. Persky, MD, professor of otolaryngology—head and neck surgery and director of the Head and Neck Center, has been elected president of the American Laryngological, Rhinological and Otological Society. Known as the Triological Society, it is the most prestigious professional society in the field of otolaryngology. The society's mission is to help otolaryngologist—head and neck surgeons and other healthcare professionals maintain and enhance their knowledge and skills as they improve patient care through education, research, and fellowship. For those who are committed to research and related scholarly activity, the society offers fellowship with peers who share common values, interests, and concerns.

Dr. Persky's one-year term as president will begin in April 2017. "It is an honor to lead the Triological Society and to support its efforts to attract, develop, and mentor the best otolaryngologists to become scholars and leaders," says Dr. Persky.

↑ Mark S. Persky, MD, and Kenneth S. Hu, MD

Imaging Illuminates Planning in Complex Cases

Coordinated Plan, PEEK Implant Resolve Years-Long Struggle with Dysplasia

A 24-year-old international student enrolled at a college in New York was referred to Adam S. Jacobson, MD, associate professor of otolaryngology—head and neck surgery and associate director of the Division of Head and Neck Surgery, with an acutely swollen left forehead and eyelids, with severe proptosis of the left globe. The young man had suffered for years with repeated infections requiring antibiotic therapy, but was told by his doctors at home that nothing could be done. Imaging at NYU Langone revealed extensive fibrous dysplasia with an acute area of infection in the left frontal bone and orbit.

The patient was admitted to the Medical Center and treated with antibiotics for his infection. After discharge, he developed two more serious infections of the same area, which required hospital admission for IV antibiotics and ultimately a lateral canthotomy, a tarsorrhaphy, and drainage of his left frontal bone abscess to resolve swelling and protect his cornea.

A CUSTOMIZED IMPLANT, PLACED WITH VIRTUAL GUIDANCE

With the infection in check, Dr. Jacobson, in collaboration with David A. Staffenberg, MD, professor of pediatrics and neurosurgery and chief of Pediatric Plastic Surgery, and David H. Harter, MD, assistant professor of neurosurgery and director of Pediatric Cerebral Endoscopy at Tisch Hospital, developed a virtual, software-aided surgical plan. The plan prioritized removal of the fibrous dysplasia, along with the patient's entire left frontal bone, ethmoids, and orbital bones under virtual guidance. The clinicians also designed a patient-specific implant using PEEK (polyetheretherketone), which is an extremely strong thermoplastic material that mimics the plasticity of cortical bone and is invisible on imaging. The implant would help reposition the patient's eye and replace the diseased frontal bone—potentially preventing future infections and restoring the patient's appearance.

OUTCOME: CONDITION RESOLVED, APPEARANCE RESTORED

"After a successful six-hour procedure, the young man's diseased bone was completely removed and his appearance was transformed," says Dr. Jacobson. His left eye, which had been severely displaced for his entire adult life, was repositioned into a much more natural and symmetrical position. Remarkably, the patient was discharged home on postoperative day three and experienced an uncomplicated postoperative course. Within weeks, he was able to return to his studies.

"Using virtual planning and PEEK enables us to achieve excellent cosmetic outcomes in some of the most complex cases," says Dr. Jacobson. "This technology supports and enhances the multidisciplinary team approach, creating an environment that allows us to work together to precisely define our plan before we even enter the operating room."

↑ Adam S. Jacobson, MD

↑ Preoperative anatomy overlaid with a virtual surgical planning maxillofacial marking guide

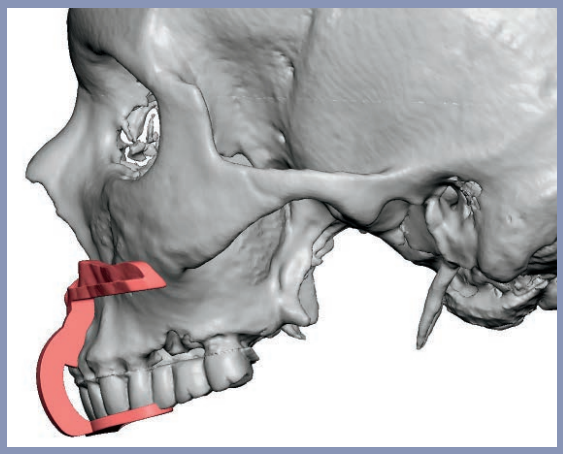

↑ Simulated maxilla marking guide

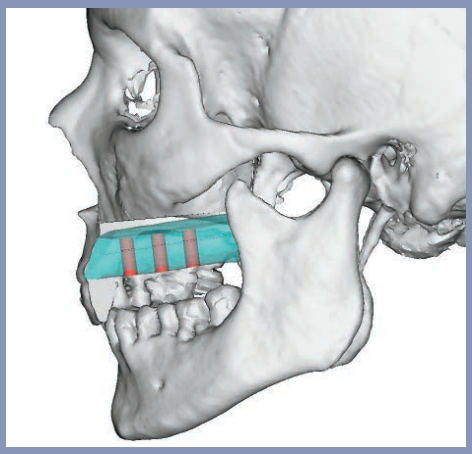

↑ Simulated maxilla reconstruction

Virtual Planning Enables Same-Day Restoration in Carcinoma Case

A 64-year-old woman was diagnosed with squamous cell carcinoma of her maxillary alveolus and hard palate. Plans were then developed to remove her upper jawbone, including half of her hard palate, while simultaneously restoring function to the area.

SURGICAL PLAN PRIORITIZES TUMOR REMOVAL, FUNCTION

The patient was referred for consultation with Dr. Jacobson, who recommended an osteocutaneous free-flap reconstruction of her left upper jawbone to re-create the hard palate and the alveolar ridge. This plan would re-create the separation between the sinonasal tract and the oral cavity and enable placement of osseointegrated dental implants at the time of the tumor extirpation and free flap reconstruction. To devise the treatment plan, Dr. Jacobson collaborated with Jamie P. Levine, MD, associate professor of plastic surgery and chief of the Division of Microsurgery, Lawrence E. Brecht, MD, clinical assistant professor of plastic surgery, and David L. Hirsch, DDS, MD, clinical assistant professor of oral and maxillofacial surgery.

OUTCOME: A FASTER ROAD TO RESTORATION

The team's three-dimensional surgical plan resulted in eradication of the patient's tumor, same-day reconstruction of the maxillary infrastructure using bone from the patient's fibula, and primary placement of three dental implants. The procedure completely restored the patient's natural appearance with just one surgery, versus the three or four surgeries that the process previously required.

"Patients used to endure 6 to 12 months without a full functional restoration, but now, using three-dimensional planning, we can extirpate a tumor, reconstruct the framework of the jaw, and place dental implants in a single surgery—drastically reducing the lag time between tumor removal and full restoration."

—Adam S. Jacobson, MD

GUARD Center a Referral Hub for Complex Pediatric Aerodigestive Cases

At the Gastroesophageal, Upper Airway, and Respiratory Diseases (GUARD) Center, cross-disciplinary specialists treat breathing, speaking, and swallowing disorders and craniofacial malformations. The center's breadth of expertise makes it a referral hub for complex cases.

SURGEONS CORRECT CONGENITAL MALFORMATION, ENABLE BREATHING

One recent GUARD Center case involved a six-year-old boy diagnosed with Nager syndrome, a rare condition that causes malformations in the bones and muscles of the face and upper extremities. The patient had a very small lower jaw and had been fitted with a tracheostomy tube shortly after birth to assist him with breathing.

Scott M. Rickert, MD, assistant professor of otolaryngology—head and neck surgery, pediatrics, and plastic surgery, in tandem with Joseph McCarthy, MD, Lawrence D. Bell Professor of Plastic Surgery, reconstructed the boy's jaw and expanded the airway in two operations, first reconstructing the mandible, then removing the tracheostomy tube. Before the first surgery, the team used three-dimensional modeling and printing of the jaw and the airway to determine how far to adjust for normal airflow, says Dr. Rickert, and then they rebuilt the mandible using bone from the patient's fibula.

"When this patient came to us, he had very little lower jaw and his mouth was the size of a tiny pinhole," Dr. Rickert says. "Now, he can breathe very well and has a more normal appearance, with his upper and lower jaws in proportion."

RECONSTRUCTION LESSENS ASTHMA'S AIRWAY BURDEN

In another case, the airway team worked with pulmonologists and allergists to expand the airway of a young girl whose severe asthma and breathing problems made it difficult for her to climb even one flight of stairs. After making a diagnosis of subglottic stenosis below the vocal fold, Dr. Rickert widened the patient's airway with endoscopic balloon dilation—but the airway continued to constrict.

To reconstruct and expand the patient's airway, Dr. Rickert and Robert F. Ward, MD, professor of otolaryngology and pediatrics and chief of the Division of Pediatric Otolaryngology harvested rib cartilage grafts and fashioned them into boat-like strips that they then placed to expand the tracheal airway. After the four-hour surgery, the patient remained in the hospital for three days without a breathing tube. She noted significant improvement in her breathing during her stay. Soon after she was discharged, her asthma symptoms improved dramatically and she was able to engage in normal activities.

SPECIALIZED SURGICAL TECHNIQUES, MULTIDISCIPLINARY APPROACH

The GUARD Center is also one of only a few worldwide performing pediatric vocal fold reanimations, an innovative procedure that restores function in vocal fold paralysis following cardiac or thoracic surgery.

The procedure reinnervates the vocal fold with a different nerve, explains Dr. Rickert. "We cut the nonfunctioning nerve and plug in a new, working nerve to give the vocal fold a new power source and make it more tone appropriate."

In complex cases, GUARD specialists collaborate with sleep specialists, dentists, psychiatrists, and neurologists, notes Dr. Rickert. "With our combined expertise, we often receive referrals for the most complex cases," he adds.

New Frontiers in Facial Reanimation Surgery for Paralysis

NYU Langone facial plastic surgeons are using new and sophisticated techniques to treat facial paralysis that can occur following tumor surgery, trauma, or Bell's palsy. In several recent cases, surgeons successfully used the masseteric nerve to reanimate facial muscles that control smiling and other movements.

MASSETERIC NERVE OFFERS SURGICAL ADVANTAGES

"Masseteric nerve transfer is typically recommended for patients who have experienced paralysis for less than two years and still have viable muscles in the affected areas," says Judy W. Lee, MD, assistant professor of otolaryngology—head and neck surgery and chief of Facial Plastic and Reconstructive Surgery. Offered by only a few specialty centers, the technique involves separating the masseteric nerve from the masseter muscle—which controls chewing—and attaching the masseteric nerve to the nonworking facial nerve.

"The hypoglossal nerve has been traditionally used to treat facial paralysis, but new research suggests that using the masseteric nerve may lead to better outcomes," says Dr. Lee. "The masseteric nerve is closer to the facial nerve, allowing it to be attached directly without an additional graft, and with its high density of motor axons it produces stronger muscle contractions for a more natural feeling smile."

COMPLEX CASE: RESTORING EXPRESSION AND PRESERVING VISION THROUGH FACIAL REANIMATION

A man who had experienced paralysis following an acoustic neuroma resection was seen in the Division of Otolaryngology—Head and Neck Surgery. The patient had lost function in smiling, speaking, and eating, and he could not close his left eye. His treatment involved transfer of the masseteric nerve and facial reconstruction.

For the nerve transfer, W. Matthew White, MD, clinical assistant professor of otolaryngology—head and neck surgery, and Adam S. Jacobson, MD, associate professor of otolaryngology—head and neck surgery and associate director of the Division of Head and Neck Surgery, made a small incision near the front of the patient's ear. They separated the long motor nerve branch from the masseter muscle, leaving the short nerve branch intact and retaining function of the masseter muscle. Next, they created a microsurgical connection between the facial and masseter nerve, triggering regeneration of the paralyzed area. Dr. White addressed the patient's vision and cosmetic problems by implanting a small platinum weight to help his upper left eyelid close and performing an eyebrow lift to eliminate hanging tissue that had caused asymmetry.

The patient is recovering well, and is expected to continue to improve over the next one to two years through rehabilitation, notes Dr. White.

"Previously, this patient could not smile, and he risked losing his sight due to dry eye," adds Dr. White. "Now, he can speak and eat normally and his eye is lubricated and protected."

Interpreting Clues to Diagnose and Treat Dizziness

When a patient complains of dizziness, the process of identifying its source can be complex. At NYU Langone, the presentation of dizziness mobilizes a multidisciplinary team of otolaryngologists, audiologists, otologists, neurologists, and vestibular physical therapists who work as one to determine the cause of the problem and initiate appropriate plans of care.

EYE MOVEMENTS ILLUMINATE PATH TO ELUSIVE CONDITION

In the case of persistent postural-perceptional dizziness (PPPD), an under-recognized diagnosis in patients with vestibular symptoms, diagnosis can be particularly difficult because the condition lacks definitive clinical diagnostic tests.

PPPD is often triggered by an event that causes acute vertigo, such as a fall, a vestibular disorder—such as Ménière's disease or neuritis—or panic attacks and anxiety. Patients often complain of unsteadiness, have difficulty with reading and other complex visual tasks, and tend to feel better when lying down. Although the results of vestibular tests cannot be used to diagnose PPPD, they may identify comorbid conditions stemming from disorders of the inner ear that affect balance.

These tests, performed in the audiology suite, look for abnormal eye movements in response to vestibular stimuli, which may indicate a vestibular system condition, such as superior canal dehiscence or Ménière's disease.

For example, using videonystagmography, technicians measure how a patient tracks visual targets displayed through goggles equipped with infrared cameras. Technicians also assess how each ear responds to stimulation by placing cool and warm air into the ear canals and monitoring the patient's eye movements. Another test, vestibular evoked myogenic potential (VEMP), stimulates the ear with high-pitched sounds or taps on the head and records the resulting contractions in the muscles that control the neck (cervical VEMP) and the eye (ocular VEMP).

RUSK REHABILITATION: A CUSTOMIZED APPROACH TO RESTORING BALANCE

Once a diagnosis is made, otolaryngologists and neurologists work closely with vestibular physical therapists and psychologists at Rusk Rehabilitation at NYU Langone, creating customized treatment plans for balance disorders such as benign paroxysmal positional vertigo (BPPV), Ménière's disease, and traumatic brain injuries.

Patients treated at Rusk for balance disorders engage in a series of exercises to leverage the body's natural compensational ability, including:

→ **Canalith repositioning** to dislodge the tiny inner ear crystals that become displaced in patients with BPPV, upsetting balance.

→ **Balance retraining exercises** to improve the coordination of muscles, joints, and vision and help steady patients' movements.

→ **Gaze stabilization exercises** involving specific eye movements to help patients' ocular muscles adapt to changes in the vestibular system.

→ **Sensory organization training** to help patients integrate visual, proprioceptive, and vestibular cues to regain posture stability.

ZEBRAFISH PROVIDE WINDOW INTO HUMAN BALANCE SYSTEM

New research examining the mechanisms of balance in zebrafish is helping to illuminate the same mechanisms in humans. Led by David E. Schoppik, PhD, assistant professor of otolaryngology—head and neck surgery and neuroscience and physiology, the research is focused on how zebrafish learn to stabilize themselves in the water, with the goal of informing new strategies to treat human balance disorders.

Both the transparency of zebrafish larvae—allowing scientists to keep them alive while they observe cellular activity—and their humanlike genetic structure make them ideal for research. Dr. Schoppik's lab developed a set of protocols that allows the researchers to molecularly target individual neurons at every stage of the larvae's vestibular circuit and to monitor the circuit as sensations (such as force) are translated into movement (such as eye rotations).

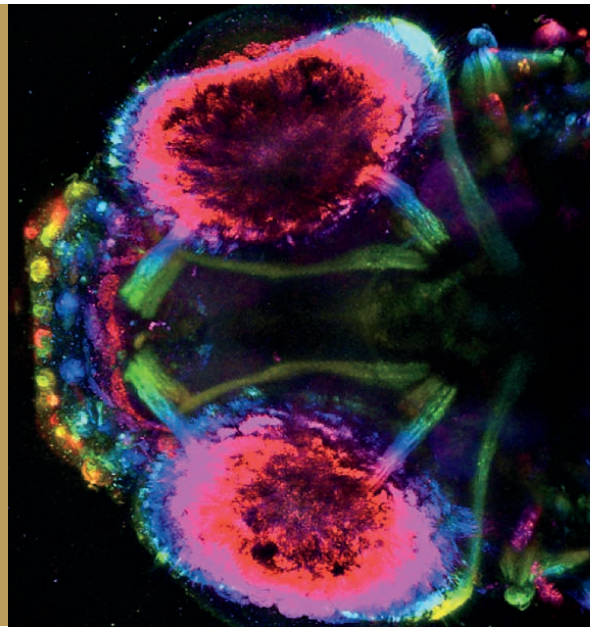

BALANCE AND POSTURE: A LEARNED RESPONSE?

In an earlier study, published in *Current Biology,* researchers measured the ability of larval zebrafish to stabilize their gaze following body rotations and identified the neurons responsible for this vital reflex. Building on those findings, recent research by Dr. Schoppik and postdoctoral fellow David Ehrlich, PhD, sheds light on how balance and posture develop as zebrafish mature.

In the larval stage, the heads of zebrafish are large relative to their bodies, similar to human toddlers. Although the fish remain top heavy as they mature, they learn to stabilize themselves as they swim and become better at correcting for the imbalance, suggesting that the process has neurological underpinnings.

To more closely observe this learning process, the researchers made baby zebrafish heavier by raising them in a mixture of oil and water so they would gulp oil instead of air upon rising to the surface. As a result, the heavier fish began to swim more frequently to restore balance. Researchers observed how fish of different ages stabilized their balance; younger fish performed these movements at a constant rate whereas more mature fish did so selectively, suggesting that they learned to respond to instability over time.

IN FISH AND IN HUMANS, TIMED MOVEMENT IS KEY

The findings fit well with observations of humans' response to imbalance, Dr. Schoppik notes. Someone who feels dizzy instinctively steps forward and shortens their steps to keep from falling. These findings suggest that the key to developing balance in both fish and humans is the learned response.

"Our study suggests that we maintain balance by moving preferentially when we're unstable," says Dr. Schoppik. "Learning to time movement initiation may be crucial for postural stability."

EXPERTISE ADDS ART TO SCIENCE OF DIAGNOSIS

Catherine Cho, MD, clinical associate professor of neurology and otolaryngology—head and neck surgery, adds a crucial layer of neurological interpretation to the results of these tests. A specialist in gait and balance impairment due to neurologic diseases such as Parkinson's, vertigo, or mal de débarquement syndrome, Dr. Cho can refine the vestibular system diagnosis by recognizing impairments that are distinct from those seen in peripheral disease. For example, mild cerebellar ataxia may result in a symptom of "dizziness" or imbalance, but there are eye movement patterns and neurological findings that can distinguish this from peripheral vestibular disease.

NYU Langone is one of only a few centers in the nation offering the specialized neurological expertise to interpret vestibular test results with precision.

"Dizziness is commonly assumed to be caused by dysfunction of the inner ear," says Dr. Cho. "But sometimes it is rooted in neurological conditions that can lead to deterioration in gait and balance if it's not recognized as a brain problem rather than an ear problem."

Collaboration Yields New Insights into Allergy, Immunology, and Otolaryngology

To Ronit Herzog, MD, associate professor of otolaryngology—head and neck surgery and pediatrics and director of Allergy and Immunology, interdisciplinary collaboration is crucial to the comprehensive evaluation and appropriate treatment of immune deficiencies and allergies.

RECURRENT CROUP LEADS TEAM TO ESOPHAGEAL DIAGNOSIS

A recent case of a six-year-old boy with recurrent croup who was ultimately diagnosed with eosinophilic esophagitis (EoE) underscores the benefits of this interdisciplinary collaboration. Although children with EoE typically present with gastrointestinal symptoms, such as food intolerance, emesis, dysphagia, food impaction, or poor weight gain, this patient presented with recurrent croupy cough and choking sensation. His symptoms persisted despite therapy for acute sinusitis, following a nasal scope that revealed thick discharge. His vital signs, physical examination, and laboratory tests appeared normal, and immunoglobulin E (IgE) testing did not reveal any food or environmental sensitivities.

Through an expedient team effort by allergists and immunologists, otolaryngologists, and gastroenterologists, endoscopy and esophageal biopsies were subsequently performed, revealing eosinophil infiltrate—the presence of a type of white blood cell not found in normal esophageal tissue. Elimination of dairy and milk products led to the resolution of the patient's symptoms and pathology.

"In this case, a team effort led to a lesser-known diagnosis: EoE that presented with upper airway symptoms, including recurrent croup and a throat-closing sensation," says Dr. Herzog. "With timely intervention, we were able to reverse the condition."

INCREASING EVIDENCE SUPPORTS INTRODUCTION OF ALLERGENIC FOODS

Although dietary elimination is critical in certain situations, early introduction of food—even in early infancy—may be important in others. A recent case managed by Dr. Herzog offers new insights supporting this shifting paradigm. A four-month-old infant developed atopic dermatitis and was hospitalized for poor weight gain. She was diagnosed with a milk protein allergy, and her allergen-specific type I IgE was very high for soy, egg white, rice, wheat, and peanut. With close monitoring by Dr. Herzog, all foods were introduced except milk, which had already elicited an allergic reaction. The patient showed no new symptoms of allergic reactions and has maintained food tolerance during the five years of follow-up since her initial care.

"This case highlights the potential benefit of introducing allergenic foods in early infancy, which may actually prevent the need for extensive lifelong dietary elimination," notes Dr. Herzog.

ONGOING RESEARCH TARGETS FOOD ALLERGIES, NEW DISORDERS

New studies by Dr. Herzog and colleagues are aimed at improving quality of life for those with allergic and immune disorders. One such study is examining the immune regulatory changes necessary for food-allergic patients to develop food tolerance. In another, Dr. Herzog is collaborating with the National Institutes of Health's National Institute of Allergy and Infectious Diseases to examine a newly diagnosed category of autoinflammatory disorders and determine whether an interleukin-1 receptor antagonist might be therapeutic for these patients.

Novel Brain Cooling Technique Uncovers Roles of Brain Regions in Speech Production

Efforts to understand where and how the brain encodes and produces speech could lead researchers and clinicians to novel therapies and better-targeted rehabilitation methods.

INNOVATIVE PROBE HIGHLIGHTS NUANCED NEURAL FUNCTION

A novel electronic probe that mildly cools down quarter-sized patches of brain cells helped to clarify the function of two key brain circuits that underlie human speech. The probe, which cools the nerve cells by about seven degrees Celsius, was invented by Michael A. Long, PhD, assistant professor of otolaryngology—head and neck surgery and neuroscience and physiology.

Building on similar findings from their study of the brain regions contributing to song production in the zebra finch, Dr. Long and his research team used the probe on 22 neurosurgical patient volunteers undergoing neurosurgery to address epilepsy or to remove brain tumors. These individuals were awake prior to surgery in order to supplement perioperative brain mapping, which identifies speech-oriented brain regions so that these areas can be protected during the procedure.

The study, published in *Neuron*, was conducted in collaboration with Mario A. Svirsky, PhD, the Noel L. Cohen Professor of Hearing Science and professor of neuroscience and physiology, and colleagues at the University of Iowa. Its aim was to learn more about key speech centers and show that the cooling probe could be a safe, effective alternative to standard methods used for brain function mapping—typically the administration of electrical current, which carries the risk of triggering seizures.

"Unlike traditional mapping with electrical stimulation, which completely—though temporarily—knocks out speech, our probe causes more nuanced changes to neural function in the areas where it is placed," explains Dr. Long. "We found that when we cooled Broca's region and had patients perform simple speech tasks, it changed the timing of their speech, slowing it down. When we cooled the speech motor cortex, on the other hand, it affected the quality of their speech—it became slurred."

The researchers next plan to use recording methods, including the NeuroGrid (also an NYU Langone invention), to study electrical activity in these speech regions in greater detail.

A FUNCTIONAL MAP OF SPEECH PRODUCTION BASED ON DATA FROM 16 PATIENT VOLUNTEERS

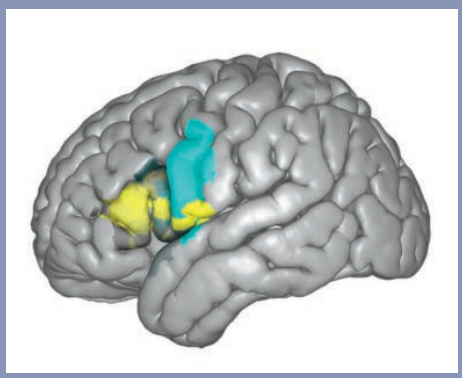

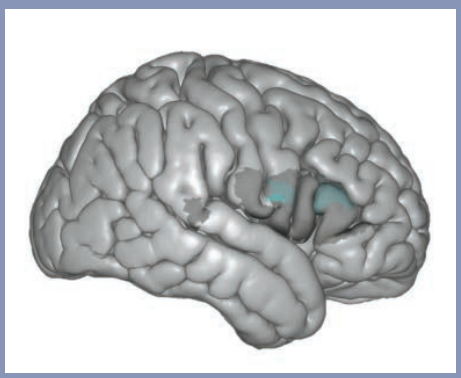

→ Left and right hemispheres of the brain. Focal cooling resulted in changes in articulation (shown in blue) and timing (yellow) that were located primarily on the left hemisphere in distinct cortical regions

Images: Long et al., 2016

Training the Next Generation

WITH THE ADDITION OF NEW LEARNING OPPORTUNITIES UNDER THE MENTORSHIP OF LEADING EXPERTS, THE DEPARTMENT OF OTOLARYNGOLOGY—HEAD AND NECK SURGERY CONTINUES TO ENHANCE AN ALREADY-UNMATCHED EDUCATIONAL EXPERIENCE.

↑ (from left) Kenneth S. Hu, MD, Allison Most, NP; Adam S. Jacobson, MD

Expanded Fellowships Deepen Learning, Draw Top Talent

HEAD AND NECK CENTER LAUNCHES NEW FELLOWSHIP. The Head and Neck Center will launch a new fellowship in fall 2017 under the direction of Adam S. Jacobson, MD, associate professor of otolaryngology—head and neck surgery and associate director of the Division of Head and Neck Surgery. The Head and Neck Oncology–Head and Neck Reconstructive Surgery Fellowship—the first of its kind at NYU Langone and one of only a handful of such programs in the country—will offer dual training in oncological and reconstructive surgery to manage complex head and neck malignancies. The fellowship's educational program involves cross-disciplinary collaborations with plastic surgery, oral maxillofacial surgery, and medical oncology.

"Gaining experience across these areas makes surgical planning less complicated," notes Dr. Jacobson. "The fellows will eventually be able to perform a greater proportion of procedures independently, allowing for smaller teams in the operating room."

Each fellow will gain experience in a variety of complex head and neck extirpations and complex reconstructive procedures, as well as minimally invasive surgical techniques, including transoral laser microsurgery, robotic-assisted surgery, and endoscopic procedures. NYU Langone surgeons are pioneers in using three-dimensional computer modeling and reconstructive techniques, including microvascular free-tissue transfer, to repair bones and soft tissues following surgery.

The new fellowship, which builds on the recent expansion of the Head and Neck Center and deepens its educational offerings, joins a slate of programs in which fellows train with an experienced, multidisciplinary head and neck team. Last year, the Department of Otolaryngology—Head and Neck Surgery separately introduced a pediatric otolaryngology fellowship under the direction of Max M. April, MD, professor of otolaryngology and pediatrics. The department also offers fellowships in neurotology, facial plastics and reconstructive surgery, and laryngology.

NEUROTOLOGY FELLOW BAISHAKHI CHOUDHURY. Baishakhi Choudhury, MD, began a two-year fellowship in neurotology in the Department of Otolaryngology—Head and Neck Surgery in July 2016. Dr. Choudhury, who completed her residency in otolaryngology—head and neck surgery at the University of North Carolina Chapel Hill, was drawn to NYU Langone because of its expertise in cochlear and auditory brainstem implantation and its high volume of cases of cerebellopontine angle tumor, along with its reputation for advancing the specialty with leading-edge research.

As a neurotology fellow, Dr. Choudhury has daily opportunities to participate in otology and neurotology surgical cases at NYU Langone's campus, as well as at the nearby NYC Health + Hospitals/Bellevue and the VA New York Harbor Healthcare System, while also taking part in basic and translational research and clinical studies investigating patient management and outcomes. "This is a unique opportunity to work alongside world-renowned neurotology experts and develop expertise in my area of research interest: hearing preservation in patients undergoing cochlear implantation," says Dr. Choudhury.

2017 OTOLOGIC SURGERY CME COURSE

In June 2017, the Department of Otolaryngology—Head and Neck Surgery will hold a CME course for practicing adult and pediatric otolaryngologists, highlighting contemporary advancements in otologic and cochlear implant surgery. The course, "Advancements in the Management of Chronic Ear Disease, Ossicular Chain Reconstruction, and Cochlear Implantation," will review current best practices in ossicular chain reconstruction, the latest stapendectomy techniques, and the changing trends in cochlear implant candidacy. Course participants will take part in didactic sessions, question and answer panels, and practical laboratory sessions. They will engage in hands-on training in NYU Langone's state-of-the-art temporal bone laboratory, which has 13 stations individually equipped with leading-edge microscopes and otologic instruments and a fluoroscopy station that allows surgeons to image and obtain immediate feedback as they work with the latest cochlear implant devices.

Select Publications

Aguiar DE, Taylor NE, Li J, Gazanfari DK, Talavage TM, Laflen JB, Neuberger H, Svirsky MA. Information theoretic evaluation of a noiseband-based cochlear implant simulator. *Hear Res*. March 2016; 333: 185–93.

Ahmed OH, Marcus S, Jacobs JB, Lebowitz RA. Evolution in Visualization for Sinus and Skull Base Surgery: From Headlight to Endoscope (Historical and looking forward). *The Otolaryngologic Clinics of North America*. 2016; in press.

Ahmed OH, Marcus S, Tauber JR, Wang B, Fang Y, Lebowitz RA. Efficacy of Perioperative Lumbar Drainage following Endonasal Endoscopic Cerebrospinal Fluid Leak Repair. *Otolaryngol Head Neck Surg*. 2017; 156(1): 52-60.

Aronoff JM, Padilla M, Stelmach J, Landsberger DM. Clinically Paired Electrodes Are Often Not Perceived as Pitch Matched. *Trends Hear*. September 18, 2016; 20.

Aronoff JM, Stelmach J, Padilla M, Landsberger DM. Interleaved Processors Improve Cochlear Implant Patients' Spectral Resolution. *Ear Hear*. March–April 2016; 37(2): e85–90.

Benedict PA, Abdou RM, Dion GR, Woo P, Branski RC, Amin MR. Association of Alirocumab Therapy with Inflammatory Lesions of the Vocal Folds: A Case Report. *The Laryngoscope*. December 9, 2016; epub ahead of print.

Branski RC, Bing R, Kraja I, Amin MR. The Role of *Smad3* in the Fibrotic Phenotype in Human Vocal Fold Fibroblasts. *The Laryngoscope*. 2016; 126(5): 1151–1156.

Branski RC, Dion GR, Best S. Letter to the Editor: Xenograft Model for Therapeutic Drug Testing in Recurrent Respiratory Papillomatosis. *Annals of Otology, Rhinology, and Laryngology*. 2016; 125(11): 947–948.

Carcea I, Insanally M, Froemke RC. Dynamics of cortical activity during behavioral engagement and auditory perception. *Nature Communications*. In press.

Cerrati EW, Ahmed OH, Rickert SM. Isolated congenital maxillomandibular synechiae. *Am J Otolaryngol*. Sep–Oct 2015; 36(5): 707–9.

Cohen S, Ma H, Kuchibhotla K, Watson BO, Buzsáki G, Froemke RC, Tsien RW. Excitation-transcription coupling in parvalbumin-positive interneurons employs a novel CaM Kinase-dependent pathway distinct from excitatory neurons. *Neuron*. 2016; 90: 292–307.

Cosetti MK, Pinkston JB, Flores JM, Friedmann DR, Jones CB, Roland JT Jr., Waltzman SB. Neurocognitive testing and cochlear implantation: insights into performance in older adults. *Clinical Interventions in Aging*. May 12, 2016; 11: 603–613.

Dion GR, Coelho PG, Teng S, Janal ML, Amin MR, Branski RC. Dynamic nanomechanical analysis of the vocal fold structure in excised larynges. *The Laryngoscope*. November 22, 2016; epub ahead of print.

Dion G, Jeswani S, Roof S, Fritz M, Coelho P, Sobierajd M, Amin MR, Branski RC. Functional assessment of the ex vivo vocal folds through biomechanical testing: a review. *Mater Sci Eng C*. 2016; 64: 444–453.

Dion GR, Teng S, Bing R, Hiwatashi N, Amin MR, Branski RC. Development of an In-Vivo Model of Laryngeal Burn Injury. *The Laryngoscope*. January 2017; 127(1): 186–190.

Eliava M, Melchior M, Knobloch-Bollmann S, Wahis J, da Silva Gouveia M, Tang Y, Ciobanu AC, del Rio RT, Roth LC, Althammer F, Chavant V, Goumon Y, Gruber T, Petit-Demoulière M, Busnelli M, Chini B, Tan L, Mitre M, Froemke RC, Chao MV, Giese G, Sprengel R, Kuner R, Poisbeau P, Seeburg PH, Stoop R, Charlet A, Grinevich V. A new population of parvocellular oxytocin neurons controlling magnocellular neuron activity and inflammatory pain processing. *Neuron*. 2016; 89: 1291–1304.

Friedmann DR, Ahmed OH, McMenomey SO, Shapiro WH, Waltzman SB, Roland JT Jr. Single-Sided Deafness Cochlear Implantation: Candidacy, Evaluation, and Outcomes in Children and Adults. *Otology & Neurotology*. February 2016; 37(2): e154–e160.

Fritz MA, Persky MJ, Fang Y, Simpson CB, Amin MR, Akst LM, Postma GN. The Accuracy of the Laryngopharyngeal Reflux Diagnosis: Utility of the Stroboscopic Exam. *Otolaryngol Head Neck Surg*. 2016; 155(4): 629–34.

Fritz MA, Rickert SM. Prevalence of Voice Disturbances in the Pediatric Craniofacial Patient Population. *Otolaryngol Head Neck Surg*. June 2016; 154(6): 1128–31.

Grant N, Wong RP, Kraus DH, Schoder H, Branski RC. Positron Emission Tomography (PET) enhancement after vocal fold injection medicalization. *ENT Journal*. 2016; in press.

Hiwatashi N, Bing R, Kraja I, Branski RC. Mesenchymal stem cells have anti-fibrotic effects on Transforming Growth Factor-β1 stimulated vocal fold fibroblasts. *The Laryngoscope*. January 2017; 127(1): E35-E41.

Horton JD, Friedmann DR, Roland JT Jr. Delayed Extradural CSF Collection Following Pediatric Cochlear Implantation: Report of Two Cases. *Otol Neurotol*. July 2016; 37(6): 654–7.

Insanally M, Trumpis M, Wang C, Chiang CH, Woods V, Bossi S, Froemke RC, Viventi J. A low-cost, multiplexed μECoG system for long-term, reliable high-density recordings in rodents. *Journal of Neural Engineering*. April 2016; 13(2): 026030.

King J, Shehu I, Roland JT Jr., Svirsky MA, Froemke RC. A physiological and behavioral system for hearing restoration with cochlear implants. *J Neurophysiol*. August 1, 2016; 116(2): 844–58.

Kohlberg GD, Stewart MG, Ward RF, April MM. Evaluation and management of pediatric nasal obstruction: a survey of practice patterns. *Am J Rhinol Allergy*. July 2016; 30(4): 274–8.

Kraja I, Bing R, Hiwatashi N, Rousseau B, Nalband D, Kirshenbaum K, Branski RC. Preliminary study of a novel transfection modality for in vivo siRNA delivery to vocal fold fibroblasts. *The Laryngoscope*. December 20, 2016; epub ahead of print.

Kuchibhotla KV, Gill JV, Lindsay GW, Field RE, Papadoyannis ES, Hindmarsh Sten TA, Miller KD, Froemke RC. Parallel processing by cortical inhibition enables context-dependent behavior. *Nature Neuroscience*. January 2017; 20: 62-71.

Landsberger DM, Vermeire K, Claes A, Van Rompaey V, Van de Heyning P. Qualities of Single Electrode Stimulation as a Function of Rate and Place of Stimulation with a Cochlear Implant. *Ear Hear*. May–June 2016; 37(3): e149–59.

Lebowitz RA, Pafford W. Physiology of the Nose and Paranasal Sinuses. In Sataloff R *Comprehensive Textbook of Otolaryngology Head and Neck Surgery*. Jaypee Brothers Medical Publishers. 2016; 2: 73–79.

Long MA, Katlowitz KA, Svirsky MA, Clary RC, Byun TM, Majaj N, Oya H, Howard MA 3rd, Greenlee JD. Functional Segregation of Cortical Regions Underlying Speech Timing and Articulation. *Neuron*. March 16, 2016; 89(6): 1187–93.

Massie JP, Runyan CM, Stern MJ, Alperovich M, Rickert SM, Shetye PR, Staffenberg DA, Flores RL. Nasal Septal Anatomy in Skeletally Mature Patients With Cleft Lip and Palate. *JAMA Facial Plast Surg*. Sep 1, 2016; 18(5): 347–53.

Mitre M, Marlin BJ, Schiavo JK, Morina E, Norden S, Hackett TA, Aoki C, Chao MV, Froemke RC. A distributed network for social cognition enriched for oxytocin receptors. *Journal of Neuroscience*. February 24, 2016; 36(8): 2517–2535.

Myssiorek D, Persky M. Treatment of Carotid Paragangliomas. *Operative Techniques in Otolaryngology*. 2016; 27: 30–35.

Oettl LL, Ravi N, Schneider M, Schneider P, Mitre M, Froemke RC, Chao MV, Meyer-Lindenberg A, Grinevich V, Shusterman R, Kelsch W. Oxytocin transforms early olfactory processing for optimized information extraction in social interactions. *Neuron*. 2016; 90: 609–621.

Orlandi RR, Kingdom TT, Hwang PH, Smith TL, Alt JA, Baroody FM, Batra PS, Bernal-Sprekelsen M, Bhattacharyya N, Chandra RK, Chiu A, Citardi MJ, Cohen NA, DelGaudio J, Desrosiers M, Dhong HJ, Douglas R, Ferguson B, Fokkens WJ, Georgalas C, Goldberg A, Gosepath J, Hamilos DL, Han JK, Harvey R, Hellings P, Hopkins C, Jankowski R, Javer AR, Kern R, Kountakis S, Kowalski ML, Lane A, Lanza DC, Lebowitz R, Lee HM, Lin SY, Lund V, Luong A, Mann W, Marple BF, McMains KC, Metson R, Naclerio R, Nayak JV, Otori N, Palmer JN, Parikh SR, Passali D, Peters A, Piccirillo J, Poetker DM, Psaltis AJ, Ramadan HH, Ramakrishnan VR, Riechelmann H, Roh HJ, Rudmik L, Sacks R, Schlosser RJ, Senior BA, Sindwani R, Stankiewicz JA, Stewart M, Tan BK, Toskala E, Voegels R, Wang de Y, Weitzel EK, Wise S, Woodworth BA, Wormald PJ, Wright ED, Zhou B, Kennedy DW. International Consensus Statement on Allergy and Rhinology: Rhinosinusitis. *Int Forum Allergy Rhinol*. February 2016; 6(Suppl 1): S22–209.

Padilla M, Landsberger DM. Reduction in spread of excitation from current focusing at multiple cochlear locations in cochlear implant users. *Hear Res*. March 2016; 333: 98–107.

Persky M, Sanders B, Rosen CA, Kahane J, Fang Y, Amin MR, Branski RC. False Vocal Fold Characteristics in Presbylarynges and Vocal Fold Paresis. *Annals of Otology, Rhinology, and Laryngology*. January 1, 2017; 126(1): 42–46.

Remedio L, Gribble KD, Kim N, Hallock PT, Lee J, Delestrée N, Mentis GZ, Froemke RC, Burden SJ. Diverging roles for Lrp4 and Wnt signaling in neuromuscular synapse development during evolution. *Genes and Development*. 2016; 30: 1058–1069.

Roland JT Jr., Buchman C, Eisenberg L, Henderson L, He S, Firszt J, Francis H, Dunn C, Sladen D, Arndt S, May B, Zeitler D, Niparko JK, Emmett S, Tucci D, Chen J, McConkey Robbins A, Schwefler E, Geers A, Lederberg A, Hayes H, Hughes M, Bierer J, Schafer E, Sorkin D, Kozma-Spytek L, Childress T. Proceedings of the Annual Symposium of the American Cochlear Implant Alliance. *Cochlear Implants International*. 2016; 17(5): 211–237.

Singleton AJ, Waltzman SB. Audiometric Evaluation of Children with Hearing Loss. *Otolaryngol Clin North Am*. December 2015; 48(6): 891–901.

Sridharan S, Amin MR, Branski RC. Vocal Fold Immobility after Finger Sweep Self-Extrusion of Impacted Food in a Choking Victim. *ENT Journal*. 2016; 96(1): 33–35.

Svrakic M, Roland JT Jr., McMenomey SO, Svirsky MA. Initial Operative Experience and Short-Term Hearing Preservation Results with a Mid-Scala Cochlear Implant Electrode Array. *Otol Neurotol*. December 2016; 37(10): 1549–1554.

Tawfik KO, Golub JS, Roland JT Jr., Samy RN. Recurrent cochlear implant infection treated with exteriorization and partial mastoid obliteration. *Cochlear Implants Int*. 2016; 17(1): 58–61.

Won JH, Tremblay K, Clinard CG, Wright RA, Sagi E, Svirsky M. The neural encoding of formant frequencies contributing to vowel identification in normal-hearing listeners. *J Acoust Soc Am*. January 2016; 139(1): 1–11.

Wong LC, Wang L, Yumita T, D'amour JA, Chen G, Chang B, Bernstein H, You X, Feng J, Froemke RC, Lin D. Effective modulation of male aggression through the lateral septum to medial hypothalamus projection. *Current Biology*. 2016; 26: 593–604.

Wrona E, Peng R, Amin MR, Branski RC, Freytes DO. Extracellular matrix for vocal fold lamina propria replacement: a review. *Tissue Engineering, Part B*. December 2016; 22(6): 421–429.

Wrona EA, Peng R, Born H, Amin MR, Branski RC, Freytes DO. Derivation and Characterization of Porcine Vocal Fold Extracellular Matrix Scaffold. *The Laryngoscope*. 2016; 126(4): 928–935.

Locations

1
Voice Center at NYU Langone
345 East 37th Street
Suite 306
New York, NY

2
Head and Neck Center at Perlmutter Cancer Center
160 East 34th Street
Seventh Floor
New York, NY

3
Ambulatory Care Center
240 East 38th Street
14th Floor
New York, NY

NYU Langone Facial Plastic and Reconstructive Surgery
240 East 38th Street
14th Floor
New York, NY

4
NYU Langone Otolaryngology and Audiology at Long Island
173 Froehlich
Farm Boulevard
Woodbury, NY

NYU Langone Huntington Medical Group
180 East Pulaski Road
Huntington Station, NY

5
NYU Langone Otology, Neurotology, and Skull Base Surgery
550 First Avenue
Suite 7Q
New York, NY

Rhinology at NYU Langone
530 First Avenue
Suite 7Q
New York, NY

6
Cochlear Implant Center at NYU Langone
660 First Avenue
Seventh Floor
New York, NY

Select services are available on-site at the New York School for the Deaf in White Plains, NY, and at 173 Froehlich Farm Boulevard in Woodbury, NY

7
Neurofibromatosis Center at NYU Langone
160 East 32nd Street
New York, NY

8
NYU Langone at Columbus Medical
97-85 Queens Boulevard
Rego Park, NY

9
NYU Langone at Trinity
111 Broadway
Second Floor
New York, NY

10
Preston Robert Tisch Center for Men's Health
555 Madison Avenue
Second Floor
New York, NY

11
Joan H. Tisch Center for Women's Health
207 East 84th Street
New York, NY

12
NYU Lutheran Medical Center
150 55th Street
Brooklyn, NY

13
NYU Langone Ambulatory Care West Side
355 West 52nd Street
New York, NY

14
NYU Lutheran Associates-Ovington Medical
355 Ovington Avenue
Suite 103
Brooklyn, NY

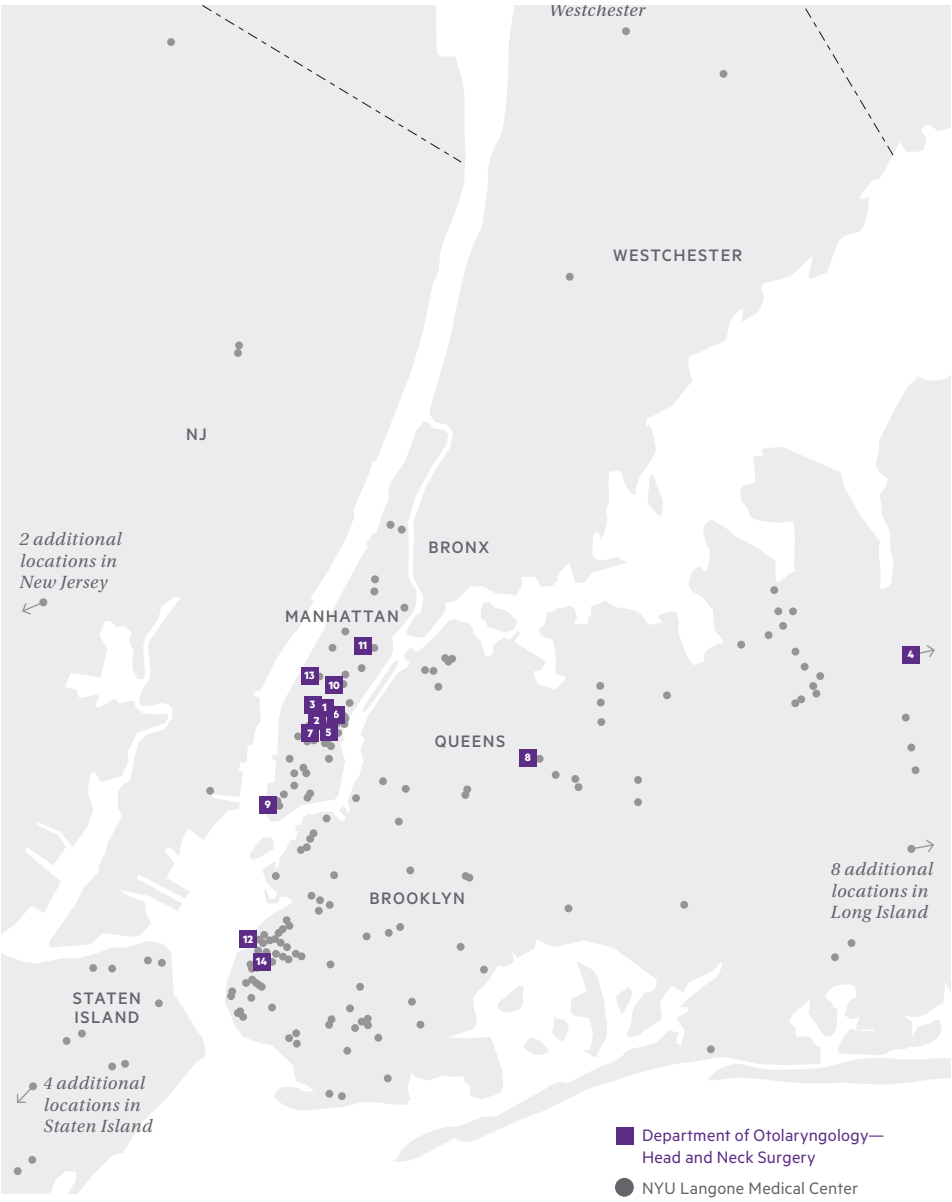

CONTACT INFORMATION

J. Thomas Roland Jr., MD

Mendik Foundation Professor of Otolaryngology
Professor of Neurosurgery
Chair of Department of Otolaryngology—Head and Neck Surgery
550 First Avenue – NBV 5E5
New York, NY 10016
212.263.7338
J.Thomas.RolandJr@nyumc.org

Faculty

J. Thomas Roland Jr., MD
Mendik Foundation Professor of Otolaryngology
Professor of Neurosurgery
Co-Director, Cochlear Implant Center at NYU Langone
Program Director, Neurotology Fellowship
Chair of Department of Otolaryngology—Head and Neck Surgery

Allergy

Ronit Herzog, MD
Associate Professor of Otolaryngology and Pediatrics
Division Chief, Allergy and Immunology

Facial Plastic and Reconstructive Surgery

Judy W. Lee, MD
Assistant Professor of Otolaryngology
Division Chief, Facial Plastic Reconstructive Surgery

Philip J. Miller, MD
Clinical Assistant Professor of Otolaryngology
Program Director, Facial Plastic Reconstructive Surgery Fellowship

W. Matthew White, MD
Clinical Assistant Professor of Otolaryngology, Facial Plastic and Reconstructive Surgery

General Otolaryngology and Sleep Surgery

Anthony Cornetta, MD
Clinical Assistant Professor of Otolaryngology

Seth E. Kaplan, MD
Assistant Professor of Otolaryngology
Chief of Service, Otolaryngology—Head and Neck Surgery, NYU Lutheran

Mohsen A. Habib, MBBCH
Clinical Assistant Professor, Department of Otolaryngology—Head and Neck Surgery at NYU Lutheran

David I. Kaufman, MD
Associate Professor of Otolaryngology

Stephen G. Rothstein, MD
Clinical Associate Professor of Otolaryngology

Michael Slippen, MD
Clinical Assistant Professor of Otolaryngology

Erich P. Voigt, MD
Clinical Associate Professor of Otolaryngology
Division Chief, General/Sleep Otolaryngology

Gerald West, DO
Clinical Assistant Professor of Otolaryngology

Head and Neck Surgery and Oncology

Mark D. DeLacure, MD
George E. Hall Associate Professor of Head and Neck Cancer Research
Associate Professor of Otolaryngology, Neurosurgery, and Hansjorg Wyss Department of Plastic Surgery
Division Chief, Head and Neck Surgery

Babak Givi, MD
Clinical Assistant Professor of Otolaryngology
Patient Safety/Quality Improvement Officer

Adam S. Jacobson, MD
Associate Professor of Otolaryngology
Director, Head and Neck Surgery Fellowship

Mark S. Persky, MD
Professor of Otolaryngology
Director, Head and Neck Center

Theresa Tran, MD
Adjunct Assistant Professor of Otolaryngology
Program Director, Bellevue Hospital Center

Cochlear Implant Center, Neurotology, Otology, and Skull Base Surgery

J. Thomas Roland Jr., MD
Mendik Foundation Professor of Otolaryngology
Professor of Neurosurgery
Co-Director, Cochlear Implant Center at NYU Langone
Program Director, Neurotology Fellowship
Chair of Department of Otolaryngology—Head and Neck Surgery

Susan B. Waltzman, PhD
Marica F. Vilcek Professor of Otolaryngology
Co-Director, Cochlear Implant Center at NYU Langone

David R. Friedmann, MD
Assistant Professor of Otolaryngology

Paul E. Hammerschlag, MD
Clinical Associate Professor of Otolaryngology

Daniel Jethanamest, MD
Assistant Professor of Otolaryngology
Director, Division of Otology-Neurotology

William H. Shapiro, AuD
Lester S. Miller, Jr. & Kathleen V. Miller Clinical Assistant Professor of Hearing Health
Director, Audiology

Pediatric Otolaryngology

Max M. April, MD
Professor of Otolaryngology and Pediatrics
Director, Pediatric Otolaryngology Fellowship

Kim A. Baker, MD
Clinical Assistant Professor of Otolaryngology
Director, Pediatric Otolaryngology—Head & Neck Surgery, NYU Lutheran

Scott M. Rickert, MD
Assistant Professor of Otolaryngology, Pediatrics, and the Hansjorg Wyss Department of Plastic Surgery
Director, Pediatric Otolaryngology at Bellevue Hospital Center

Robert F. Ward, MD
Professor of Otolaryngology and Pediatrics
Vice Chair of Clinical Affairs
Division Chief, Pediatric Otolaryngology

Research

Mario A. Svirsky, PhD
Noel L. Cohen Professor of Hearing Science
Vice Chair, Research

Susan B. Waltzman, PhD
Marica F. Vilcek Professor of Otolaryngology
Co-Director, Cochlear Implant Center at NYU Langone

Mahan Azadpour, PhD
Adjunct Professor of Otolaryngology

Ryan C. Branski, PhD
Associate Professor of Otolaryngology
Associate Director, Voice Center at NYU Langone

Robert C. Froemke, PhD
Assistant Professor of Otolaryngology and Neuroscience & Physiology

Aaron M. Johnson, PhD, MM
Assistant Professor of Otolaryngology

David M. Landsberger, PhD
Assistant Professor of Otolaryngology

Michael A. Long, PhD
Assistant Professor of Otolaryngology and Neuroscience & Physiology

Arlene C. Neuman, PhD
Research Associate Professor of Otolaryngology

David E. Schoppik, PhD
Assistant Professor of Otolaryngology and Neuroscience & Physiology

Elad Sagi, PhD
Research Assistant Professor of Otolaryngology

Chin-Tuan Tan, PhD
Research Assistant Professor of Otolaryngology

Binhuan Wang, PhD
Adjunct Professor of Otolaryngology

Monica Padilla, PhD

Natalia Stupak, AuD

Ann Todd, PhD

Annette Zeman, AuD

Jonathan Neukam, AuD

Roozbeh Soleymani, MS

Rhinology

Joseph B. Jacobs, MD
Professor of Otolaryngology

Richard A. Lebowitz, MD
Associate Professor of Otolaryngology
Vice Chair, Academic Affairs
Division Chief, Rhinology
Program Director, Otolaryngology Residency

Seth M. Lieberman, MD
Assistant Professor of Otolaryngology
Associate Program Director, Otolaryngology Residency

Voice Center

Milan R. Amin, MD
Associate Professor of Otolaryngology
Director, Voice Center at NYU Langone
Division Chief, Laryngology
Program Director, Laryngology Fellowship

Ryan C. Branski, PhD
Associate Professor of Otolaryngology
Associate Director, Voice Center at NYU Langone
Director, Resident Research

Paul E. Kwak, MD, MM, MSc
Assistant Professor of Otolaryngology

Aaron M. Johnson, PhD, MM
Assistant Professor of Otolaryngology

Audiology/Speech Language Pathology

William H. Shapiro, AuD
Director, Audiology

Matina Balou, PhD, CCC-SLP, BCS-S

Erin Bean, AuD

Gail M. Biscow, MA

Betsy Bromberg, MA

Kaitlyn M. Tona, AuD

Rosemarie A. Drous, MEd

Catherine Flynn, AuD

Kit S. Frank, AuD

Shirley Gherson, MA, CCC-SLP

Janet Green, AuD

Laurel Mahoney, AuD

Jacqueline Mojica, MS, CCC-SLP

Michelle Neidleman Kennedy, AuD

Irina Ozersky, AuD

Carie Page, AuD

Alison J. Rigby, AuD

Sara Toline, MA, CCC-SLP

Administration

Alex Curran, HC-MBA
Administrator, Department of Otolaryngology—Head and Neck Surgery

Kristin Montella, MPA
Division Administrator, Research and Education

Collaborators with Joint Appointments

Catherine Cho, MD
Clinical Associate Professor of Neurology and Otolaryngology

John G. Golfinos, MD
Associate Professor of Neurosurgery and Otolaryngology
Chair, Department of Neurosurgery

Matthias A. Karajannis, MD
Associate Professor of Pediatrics and Otolaryngology

Kepal N. Patel, MD
Associate Professor of Surgery and Biochemistry and Molecular Pharmacology
Associate Professor of Otolaryngology
Division Chief, Endocrine Surgery

Brian L. Schmidt, MD, PhD, DDS
Professor of Oral and Maxillofacial Surgery
Professor of Otolaryngology and Neuroscience & Physiology, and the Hansjorg Wyss Department of Plastic Surgery

Voluntary Faculty

Michael C. Burnett, MD
Clinical Assistant Professor of Otolaryngology

Anthony Cornetta, MD
Clinical Assistant Professor of Otolaryngology

Kamran S. Jafri, MD
Clinical Assistant Professor of Otolaryngology

Stefan Kieserman, MD
Adjunct Assistant Professor of Otolaryngology

Stephen J. Marra, MD
Adjunct Assistant Professor of Otolaryngology

Sean O. McMenomey, MD
Adjunct Professor of Otolaryngology

Richard L. Nass, MD
Clinical Associate Professor of Otolaryngology

Nilesh D. Patel, MD
Clinical Associate Professor of Otolaryngology

Benjamin C. Paul, MD
Clinical Instructor of Otolaryngology

Harvey M. Plasse, MD
Clinical Associate Professor of Otolaryngology

Lesley Rabach, MD
Adjunct Assistant Professor of Otolaryngology

Raymond L. Yung, MD
Clinical Assistant Professor of Otolaryngology

Marc Zimbler, MD, FPRS
Adjunct Assistant Professor of Otolaryngology

For more information about our physicians, services, and locations, visit **nyulangone.org**

Leadership

New York University

William R. Berkley
Chair, Board of Trustees

Andrew Hamilton, PhD
President

Robert Berne, MBA, PhD
Executive Vice President for Health

NYU Langone Medical Center

Kenneth G. Langone
Chair, Board of Trustees

Robert I. Grossman, MD
Saul J. Farber Dean and
Chief Executive Officer

Steven B. Abramson, MD
Senior Vice President and
Vice Dean for Education, Faculty,
and Academic Affairs

Dafna Bar-Sagi, PhD
Senior Vice President and
Vice Dean for Science, Chief Scientific Officer

Andrew W. Brotman, MD
Senior Vice President and
Vice Dean for Clinical Affairs and Strategy,
Chief Clinical Officer

Michael T. Burke
Senior Vice President and
Vice Dean, Corporate Chief Financial Officer

Richard Donoghue
Senior Vice President
for Strategy, Planning,
and Business Development

Annette Johnson, JD, PhD
Senior Vice President and Vice Dean,
General Counsel

Grace Y. Ko
Senior Vice President for
Development and Alumni Affairs

Kathy Lewis
Senior Vice President for
Communications and Marketing

Joseph Lhota
Senior Vice President and
Vice Dean, Chief of Staff

Vicki Match Suna, AIA
Senior Vice President and Vice Dean
for Real Estate Development and Facilities

Nader Mherabi
Senior Vice President and Vice Dean,
Chief Information Officer

Robert A. Press, MD, PhD
Senior Vice President and Vice Dean,
Chief of Hospital Operations

Nancy Sanchez
Senior Vice President and Vice Dean
for Human Resources and Organizational
Development and Learning

NYU Langone By the Numbers*

1,519 Beds

100 Operating Rooms

145,907 Emergency Room Visits

68,602 Patient Discharges

3,850,000 Outpatient Faculty Practice Visits

9,649 Births

3,584 Physicians

4,899 Nurses

574 MD Candidates

80 MD/PhD Candidates

233 PhD Candidates

397 Postdoctoral Fellows

1,472 Residents and Fellows

4,381 Original Research Papers**

550,500 Square Feet of Research Space

$334M NIH Funding

$328M Total Grant Revenue

*Numbers represent FY16 (Sept 2015–Aug 2016) and include NYU Lutheran
**Calendar year 2015

Produced by the Office of Communications and Marketing,
NYU Langone Medical Center
Writer: Janet Colwell
Design: Ideas On Purpose, www.ideasonpurpose.com
Primary Photographer: Karsten Moran
Printing: Allied Printing Services, Inc.

On the cover: Trachea blood vessels

NYU Langone
MEDICAL CENTER

NYU LANGONE MEDICAL CENTER
550 First Avenue, New York, NY 10016

NYULANGONE.ORG